

**A COMPARISON OF PREOPERATIVE AND POSTOPERATIVE
LOWER-EXTREMITY JOINT BIOMECHANICS OF PATIENTS WITH
CAM FEMOROACETABULAR IMPINGEMENT**

Nicholas Brisson, B.Sc.

Thesis submitted to the
Faculty of Graduate and Postdoctoral Studies
in partial fulfillment of the requirements for the degree of
Master's of Science in Human Kinetics

School of Human Kinetics
Faculty of Health Sciences
University of Ottawa

© Nicholas Brisson, Ottawa, Canada, 2011

NOTE:

This thesis is assembled in article format. The first three sections consist of a general introduction, review of literature and methodology. The fourth section is comprised of two articles entitled: 1) *The Effects of Cam Femoroacetabular Impingement Corrective Surgery on Lower-Extremity Gait Biomechanics* and 2) *Preoperative and Postoperative Lower-Extremity Joint and Pelvic Kinematics During Maximal Squatting of Patients with Cam Femoroacetabular Impingement*. Finally, the fifth section consists of a general discussion and conclusion that summarize the main findings presented in the articles and address the limitations of the study.

Preoperative and Postoperative Lower-Extremity Joint and Pelvic Kinematics During Maximal Squatting of Patients with Cam Femoro-Acetabular Impingement has already been published in *The Journal of Bone and Joint Surgery (Am)*, 2011; Vol. 93, p.40-45. The other article is intended to be submitted for publication.

TABLE OF CONTENTS

LIST OF TABLES	iv
LIST OF FIGURES	v
ABSTRACT	vi
ACKNOWLEDGEMENTS	vii
INTRODUCTION	1
RELEVANCY	2
RESEARCH OBJECTIVES	3
RESEARCH HYPOTHESES	3
REVIEW OF LITERATURE	4
FEMOROACETABULAR IMPINGEMENT	4
AETIOLOGY OF CAM FAI.....	6
PATHOMECHANICS	6
TREATMENT OPTIONS.....	7
<i>Conservative Treatment</i>	7
<i>Surgical Treatment</i>	7
<i>Postoperative Care</i>	10
<i>Postoperative Rehabilitation</i>	10
OUTCOME MEASUREMENTS	12
<i>Qualitative Methods</i>	12
<i>Quantitative Methods</i>	13
ACTIVITIES OF DAILY LIVING.....	14
<i>Walking</i>	14
<i>Squatting</i>	16
METHODOLOGY	18
PARTICIPANTS	18
DATA COLLECTION PROCEDURES.....	19
<i>Motion Recordings</i>	19
<i>Ground Reaction Forces</i>	20
<i>Experimental Protocol</i>	20
DATA PROCESSING PROCEDURES	22
<i>Kinematic Analysis</i>	22
<i>Kinetic Analysis</i>	23
STATISTICAL ANALYSIS.....	25
FIRST ARTICLE	27
SECOND ARTICLE	46
DISCUSSION & CONCLUSION	61
REFERENCES	68
APPENDIX A: UNIVERSITY OF OTTAWA MOTION ANALYSIS MODEL	74
APPENDIX B: UNIVERSITY OF OTTAWA MOTION ANALYSIS MODEL MARKER PLACEMENT	75
APPENDIX C: HEIGHT-ADJUSTABLE BENCH	76
APPENDIX D: HEALTH SCIENCES AND SCIENCE RESEARCH ETHICS BOARD APPROVAL ...	77

LIST OF TABLES

Table 1. Kinematic dependent variables	24
Table 2. Kinetic dependent variables	24
Table 3. Descriptive characteristics of the control, preoperative FAI and postoperative FAI participants	31
Table 4. Kinematic and kinetic variables found to be statistically significantly different between the control, preoperative FAI and postoperative FAI participants	36
Table 5. Preoperative and postoperative descriptive characteristics of participants with cam femoroacetabular impingement	50
Table 6. Preoperative and postoperative hip, knee and ankle joint angles, and the sum of all joint angles in the sagittal plane of the affected limb at maximal squat depth, and the maximal squat depth as a percentage of leg length for each participant	54

LIST OF FIGURES

Figure 1. Average sagittal plane hip angles of the preoperative FAI, postoperative FAI and healthy control groups during level walking	39
Figure 2. Average frontal plane hip angles of the preoperative FAI, postoperative FAI and healthy control groups during level walking	40
Figure 3. Average frontal plane hip moments of the preoperative FAI, postoperative FAI and healthy control groups during level walking	40
Figure 4. Mean pelvic pitch (in degrees) of the preoperative and postoperative FAI groups during maximal depth squatting	56

ABSTRACT

Surgery to correct cam femoroacetabular impingement (FAI) is increasingly popular. Despite this, no known study has used motion analysis and ground reaction forces to quantify the outcome of surgery for FAI. The goal of this study was to compare the preoperative and postoperative lower-extremity joint kinematic and kinetic measurements of cam FAI patients during activities of daily living with use of a high-speed motion capture system and force platforms. We hypothesized that the lower-extremity joint mechanics of FAI patients during level walking and maximal squatting would resemble more those of healthy control subjects, after surgery. Ten patients with unilateral symptomatic cam FAI, who underwent corrective surgery using an open or combined technique, performed walking and maximal depth squatting trials preoperatively and postoperatively. Thirteen healthy control subjects, matched for age, sex and body mass index, provided normative data. Results showed that postoperatively, FAI patients had reduced hip ROM in the frontal and sagittal planes, produced smaller peak hip abduction and external rotation moments, and generated less peak hip power compared to the control group during level walking. During maximal squatting, postoperative FAI patients squatted to a greater depth, and had larger knee flexion and ankle dorsiflexion angles, as well as the sum of all joint angles of the affected limb at maximal depth compared to the preoperative values. The lower-extremity joint and pelvic mechanics of FAI patients did not fully return to normal after surgery. Although surgery seemed to reduce hip pain and restore a normal femoral head-neck offset, it further impaired muscle function as a result of muscle incisions. More research is needed to determine the effects of muscle incisions, which could help improve surgical techniques and develop better rehabilitation programs for FAI patients.

ACKNOWLEDGEMENTS

I would like to thank the members of my committee, Dr. Paul Beaulé and Dr. Daniel Benoit, for their constructive recommendations and insight during the development of this project. I would also like to thank my fellow lab mates (D.V., G.M., T.F.) for their problem solving skills and recurrent willingness to lend a helping hand. A distinguished thank you goes out to my supervisor, Dr. Mario Lamontagne, for his guidance and patience throughout this process. Finally, I would like to express my gratitude to my family and friends (AD.G., C.M., L.O., M.L.) for their support and understanding, helping me complete this journey.

INTRODUCTION

Cam femoroacetabular impingement (FAI), a chronic pathological condition of the hip characterized by an aspherical femoral head, is an increasingly recognized cause of hip and groin pain in young, active adults (Wisniewski and Grogg 2006; Beaulé, LeDuff et al. 2007). It is associated with labral and chondral damage (Eijer, Myers et al. 2001; Ganz, Parvizi et al. 2003; Lavigne, Parvizi et al. 2004; Tanzer and Noiseux 2004; Beck, Kalhor et al. 2005; Leunig, Beck et al. 2005; Philippon and Schenker 2006; Tannast, Goricki et al. 2008) and is therefore thought to be an underlying cause of hip osteoarthritis (Murray 1965; Stulberg, Cordell et al. 1975; Harris 1986; Ito, Minka-II et al. 2001; Ganz, Parvizi et al. 2003; Beck, Leunig et al. 2004b; Leunig, Beck et al. 2005).

FAI has been shown to negatively alter hip joint biomechanics – particularly its range of motion (ROM) in all three planes (Ito, Leunig et al. 2004; Clohisy, Nunley et al. 2007; Philippon, Maxwell et al. 2007; Lamontagne, Kennedy et al. 2009; Kennedy, Lamontagne et al. 2009a; Kennedy, Lamontagne et al. 2009b) – which, in turn, can limit one's capability of accomplishing functional tasks such as walking, sitting and standing, squatting and stair climbing. These tasks are performed on a daily basis by most individuals and require adequate hip joint mobility, thus an inability to perform them could drastically reduce one's quality of life.

Several surgical procedures (Ganz, Gill et al. 2001; Clohisy and McClure 2005; Philippon and Schenker 2006) have been developed to correct FAI by removing the bony abnormality from the femoral head-neck junction (Ganz, Gill et al. 2001; Lavigne, Parvizi et al. 2004; Leunig, Beck et al. 2005), thus attenuating hip pain (Peters and Erickson 2006; Beaulé, LeDuff et al. 2007; Ilizaliturri Jr, Orozco-Rodriguez et al. 2008; Byrd and Jones

2009; Lincoln, Johnston et al. 2009), and reducing or eliminating the risks of developing hip osteoarthritis (Ganz, Gill et al. 2001; Lavigne, Parvizi et al. 2004; Leunig, Beck et al. 2005).

Although numerous studies have evaluated the mechanics of healthy and pathologic lower-extremity joints during various functional tasks, to our knowledge, no study has compared the preoperative and postoperative lower-extremity joint biomechanics of patients with cam FAI. It is important to conduct such a study to determine if surgical intervention is beneficial or detrimental in improving hip function. The use of motion analysis and ground reaction forces can provide this important information regarding lower-extremity joint function following hip surgery (Bhave, Marker et al. 2007).

Relevancy

Many studies have measured the outcome of cam FAI surgery either qualitatively, using validated questionnaires, or quantitatively, comparing the passive ROM of affected hips before and after corrective surgery. Despite this, no known study has quantitatively examined the postoperative lower-extremity joint biomechanics of cam FAI patients using three-dimensional (3-D) motion analysis. Understanding how the lower-extremity joints function during activities of daily living following correction of FAI is essential in confirming that surgical intervention effectively restores the normal biomechanics of the hip. Consequently, a return to normal hip function may indicate the cessation of femoral abutment against the acetabular rim, thus attenuating hip and groin pain, improving quality of life and reducing risks of developing joint degenerative diseases. Moreover, information gained in this study may provide valuable insight which could be used to improve surgical techniques, rehabilitation programs and postoperative care for FAI patients.

Research Objectives

The purpose of this study was to determine the effects of cam FAI corrective surgery on lower-extremity joint mechanics during level walking and maximal depth squatting by comparing 3-D angular displacements of the hip, knee, ankle and pelvis, as well as the moments and powers at the hip, knee and ankle joints of preoperative and postoperative patients with unilateral symptomatic cam FAI. For the walking condition, the preoperative and postoperative FAI groups were also compared to a healthy control group matched for age, sex and body mass index.

Research Hypotheses

The research hypotheses were drawn based on findings by Kennedy et al. (2009b) and Lamontagne et al. (2009), and were founded on the assumption that the corrective surgery for cam FAI would restore more normal lower-extremity joint mechanics in FAI patients. No specific hypotheses were drawn regarding the kinematic and kinetic measurements of the knee and ankle joints seeing as no studies were found regarding the effects of cam FAI on these joints.

Regarding the level walking condition, it was hypothesized that there would be no significant differences between the postoperative cam FAI group and the control group with regard to the hip and pelvic mechanics. Concerning the maximal depth squatting condition, it was hypothesized that, postoperatively, maximal squat depth of FAI patients would improve. It was also hypothesized that the sagittal plane pelvic ROM over the squat cycle of FAI patients would be greater postoperatively.

REVIEW OF LITERATURE

Femoroacetabular Impingement

Femoroacetabular impingement (FAI) is an idiopathic progressive pathological condition of the hip characterized by an abnormal anatomical morphology of the femoral head-neck junction and/or of the acetabulum (Beck, Leunig et al. 2004b). It occurs by abutment of the femoral neck against the acetabular rim during movements that solicit the hip's end range of motion (ROM) (Ganz, Parvizi et al. 2003). Impingement has also been reported to occur within the normal ROM of the hip (Ito, Minka-II et al. 2001). Symptoms usually include a slow onset of groin pain, which may be sporadic during the initial stages of the disease and aggravated by excessive solicitation of the hip, especially in flexion, internal rotation, and sometimes in abduction (Guanche and Bare 2006; Philippon and Schenker 2006; Laude, Boyer et al. 2007). Pain is most often felt during physical activity, prolonged walking and sitting, stair climbing and squatting (Ganz, Parvizi et al. 2003; Leunig, Beck et al. 2005; Guanche and Bare 2006; Philippon and Schenker 2006; Laude, Boyer et al. 2007). FAI can present itself in three forms: 1) cam impingement; 2) pincer impingement or 3) a combination of cam-type and pincer-type impingements (Beck, Leunig et al. 2004a).

Although the term *cam FAI* has only been recently coined by Ganz and associates (2003) to describe an abnormal junction between the femoral head and neck, the concept of such a deformity of the hip has existed for several decades. Murray (1965) first identified an abnormal morphology of the femoral head-neck junction, which he called 'tilt deformity of the femoral head'. Equally, in 1975, Stulberg and colleagues used the term 'pistol grip' to describe a somewhat flattened and disproportionate femoral head-neck junction. In all cases, cam FAI refers to an asphericity of the femoral head-neck junction, causing a localized

increase in its radius (Ganz, Parvizi et al. 2003). During hip motion, the asphericity – most often at the anterolateral aspect of the head-neck junction – jams into the acetabulum, causing impingement and pain (Ito, Minka-II et al. 2001; Nötzli, Wyss et al. 2002; Beck, Leunig et al. 2004a; Beck, Kalhor et al. 2005; Leunig, Beck et al. 2005). Cam FAI has been reported to primarily affect young and active adults (Ganz, Parvizi et al. 2003; Lavigne, Parvizi et al. 2004; Beck, Kalhor et al. 2005; Leunig, Beck et al. 2005). Markedly, a cohort study conducted by Gosvig and associates (2008) found that 17% of males and 4% of females were affected by this type of impingement.

Pincer impingement is the result of linear contact between the acetabular rim and the femoral head-neck junction. Habitually, the femoral head has a normal morphology and the abutment is caused by a deformity of the acetabulum, frequently manifested by a general over-coverage (*coxa profunda*) or a local anterior over-coverage (*acetabular retroversion*) (Ganz, Parvizi et al. 2003; Beck, Leunig et al. 2004a; Leunig, Beck et al. 2005). Pincer impingement is prevalent in middle-aged females who participate in athletic activities involving frequent hip motion (Ganz, Parvizi et al. 2003; Lavigne, Parvizi et al. 2004; Beck, Kalhor et al. 2005; Leunig, Beck et al. 2005).

Cam and pincer impingements are two mechanisms that rarely occur in isolation. Most of the time, affected hips are attained by both these types of deformities, which is classified as a mixed cam-pincer impingement. In this case, impingement is caused by abnormal anatomical morphologies of both the femoral head-neck junction and the acetabulum, accounting for the greatest range of aetiological variations (Beck, Kalhor et al. 2005). The present study focused purely on cam FAI; therefore, only this type of impingement is addressed hereon in.

Aetiology of Cam FAI

The aetiology of cam FAI has not yet been identified. However, several studies propose that some predisposing conditions may lead to an abnormal femoral head-neck junction, resulting in cam impingement. Particularly, conditions such as rotational malunion due to a previous femoral neck fracture (Eijer, Myers et al. 2001), flattening of the femoral head due to femoral head necrosis (Kloen, Leunig et al. 2002), posterior tilt of the femoral head due to slipped capital femoral epiphysis (Rab 1999), residual childhood diseases such as Perthes (Ganz, Parvizi et al. 2003) and iatrogenic reduction in joint clearance following femoral osteotomy (Myers, Eijer et al. 1999) have been linked to the onset of cam FAI.

Pathomechanics

In cam FAI, jamming of the femoral head-neck junction into the acetabulum produces repetitive low-impact localized loading at the site of impingement. The damaged bone compensates by ossifying and accumulating bone volume at the site of contact, resulting in increased severity of impingement (Ganz, Parvizi et al. 2003). In turn, this causes compression and shear stresses at the junction between the labrum and the cartilage. Explicitly, the labrum is stretched and pushed outwards while the cartilage is compressed and pushed centrally (Lavigne, Parvizi et al. 2004; Beck, Kalhor et al. 2005). As a result, the acetabular cartilage – in the anterosuperior aspect of the acetabulum – is progressively damaged, which may lead to a tear or detachment of the labrum (Eijer, Myers et al. 2001; Ganz, Parvizi et al. 2003; Lavigne, Parvizi et al. 2004; Tanzer and Noiseux 2004; Beck, Kalhor et al. 2005; Leunig, Beck et al. 2005; Philippon and Schenker 2006; Tannast, Goricki et al. 2008). Seeing as the acetabular labrum is innervated (Kim and Azuma 1995), such labral damages may be associated with being a source of pain (Fitzgerald Jr 1995).

Moreover, a deformity of the femoral head-neck junction and its related labral and chondral defects have long been thought to be an underlying cause of hip osteoarthritis (Murray 1965; Stulberg, Cordell et al. 1975; Harris 1986; Ito, Minka II et al. 2001; Ganz, Parvizi et al. 2003; Beck, Leunig et al. 2004b; Leunig, Beck et al. 2005).

Treatment Options

Conservative Treatment

When treating FAI patients, a conservative treatment is sometimes attempted. This includes modification or limitation of athletic activities to reduce extreme motion and demand on the hip. Non-steroidal anti-inflammatory drugs and analgesics can be used to relieve pain, however, they may mask the symptoms of an underlying destructive process (Lavigne, Parvizi et al. 2004; Leunig, Beck et al. 2005). Since FAI primarily affects young active adults, conservative treatment plans, which require drastic lifestyle changes and restriction of physical activities, are not ideal. As a result, FAI is mainly corrected by means of surgery (Guanche and Bare 2006).

Surgical Treatment

The aim of surgery is to improve the clearance for hip motion, particularly in flexion and internal rotation, and relieve hip pain by alleviating femoral abutment against the acetabular rim, thus halting the process of chondral and labral damage (Ganz, Gill et al. 2001; Lavigne, Parvizi et al. 2004; Leunig, Beck et al. 2005). Surgical correction of cam impingement is indicated for young patients without severe damage to articular surfaces (Beck, Leunig et al. 2004b; Leunig, Beck et al. 2005; Sampson 2005; Mardones, Gonzalez et al. 2006). Patients who have advanced degenerative changes and extensive cartilage damage are recommended to undergo total hip arthroplasty (Beck, Leunig et al. 2004b; Leunig, Beck

et al. 2005; Sampson 2005; Mardones, Gonzalez et al. 2006). Cam FAI can be treated using an open technique (Ganz, Gill et al. 2001; Lavigne, Parvizi et al. 2004; Leunig, Robertson et al. 2007), an arthroscopic technique (Sampson 2005; Weiland and Philippon 2005; Guanche and Bare 2006; Philippon and Schenker 2006) or a combination of both approaches (Clohisy and McClure 2005; Barton, Banga et al. 2009; Lincoln, Johnston et al. 2009). Only the open and combined techniques are described hereunder seeing as all FAI patients who partook in the current study were operated using one of these two approaches. It is important to note that the following descriptions provide a general outline of the surgical procedures. Some modifications are sometimes brought to the protocol depending on the site of impingement, the severity of adjoining tissue damage and the surgeon's preference.

Open Technique

The open technique, originally described by Ganz et al. (2001), is performed with the patient in lateral decubitus position. After proper prepping of the hip, two skin incisions can be made: lateral or posterior (Ganz, Gill et al. 2001; Lavigne, Parvizi et al. 2004; Leunig, Robertson et al. 2007). The superficial dissection of the muscles is done according to the approach chosen (i.e. fascia latae or gluteus maximus). Next, a trochanteric flip is performed and the vastus lateralis, gluteus medius and gluteus minimus are mobilized (Ganz, Gill et al. 2001; Leunig, Robertson et al. 2007). An anterior capsulotomy is then performed, followed by an anterior dislocation of the hip, which allows a 360° view of the femoral head and gives complete access to the acetabulum with minimal risk of avascular necrosis (Ganz, Gill et al. 2001; Lavigne, Parvizi et al. 2004; Beck, Leunig et al. 2004b; Kim and Millis 2005; Peters and Erickson 2006; Freccero, Providence et al. 2009). Subsequently, the acetabular labrum and adjacent articular cartilage are inspected and repaired. Then, contouring of the femoral

head and neck is done by excision osteoplasty (Ganz, Gill et al. 2001; Leunig, Robertson et al. 2007). An osteotomy of the acetabular rim and/or other procedures are performed as judged necessary to clear the impingement (Ganz, Gill et al. 2001; Leunig, Robertson et al. 2007). Upon completion, the hip is reduced, the ROM is tested, the hip joint capsule is closed up and the trochanter is affixed back onto the femur using two or three cortical screws (Ganz, Gill et al. 2001; Lavigne, Parvizi et al. 2004; Leunig, Robertson et al. 2007). Finally, the incised muscles, subcutaneous tissue and skin are stitched up (Ganz, Gill et al. 2001; Leunig, Robertson et al. 2007).

Combined Arthroscopic and Open Technique

The combined approach begins with hip arthroscopy, with the patient either in lateral or supine position. First, traction/distraction is applied to break the joint's seal. Then, the hip joint is distracted and the proximal femur is properly prepped (Clohisy and McClure 2005; Barton, Banga et al. 2009; Lincoln, Johnston et al. 2009). Next, two portals (anterolateral and anterior) are inserted near the greater trochanter to adequately and safely decompress the hip (Clohisy and McClure 2005; Barton, Banga et al. 2009; Lincoln, Johnston et al. 2009). Intra-articular pathologies such as labral and chondral defects are assessed through the portals and debrided as necessary. Following arthroscopy, traction is released (Clohisy and McClure 2005; Barton, Banga et al. 2009; Lincoln, Johnston et al. 2009). An anterior hip arthrotomy is then done through the Hueter approach with the patient positioned supine (Clohisy and McClure 2005; Barton, Banga et al. 2009; Lincoln, Johnston et al. 2009). The tensor fasciae latae is incised and the muscle belly is retracted laterally. The released heads of the rectus femoris are then reflected and a capsulotomy is performed (Clohisy and McClure 2005). With slight traction, the site of impingement is shaved under direct visualization. Upon

completion, traction is released, the ROM is tested and the hip joint capsule is closed up. Lastly, the incised muscles, subcutaneous tissue and skin are stitched up (Clohisy and McClure 2005; Barton, Banga et al. 2009; Lincoln, Johnston et al. 2009).

Postoperative Care

Patients are usually discharged on the day of surgery. Depending on the surgical approach utilized; patients are restricted to toe-touch weight bearing for either three weeks (combined technique) (Barton, Banga et al. 2009) or for six to eight weeks (open technique), allowing proper healing of the greater trochanteric osteotomy. During this period, hip flexion is limited to 70° and vigorous activities (i.e. sports) are dissuaded (Guanche and Bare 2006; Lincoln, Johnston et al. 2009). Moreover, specialized equipment such as a passive motion device and a modified hip brace or specific boots can be used during the first postoperative weeks to prevent tissue adhesions (Lavigne, Parvizi et al. 2004; Leunig, Robertson et al. 2007) and limit hip rotation and abduction (Philippon and Schenker 2006), respectively.

Postoperative Rehabilitation

FAI patients are recommended to follow a postoperative rehabilitation program to aid in their recovery. Despite this, there is a paucity of literature discussing rehabilitation protocols for this specific population. Several studies, however, were found discussing rehabilitation protocols for patients having undergone hip resurfacing and total hip arthroplasty (Enseki, Martin et al. 2010; Grotle, Garratt et al. 2010; Liebs, Herzberg et al. 2010), surgeries closely resembling that for FAI. As a result, these protocols are often used in the implementation of rehabilitation programs for FAI patients (Enseki, Martin et al. 2010). It is important to note, however, that these rehabilitation procedures may not be entirely applicable to FAI patients, mainly because the FAI population is likely to originate

from a younger and more physically active population compared to total hip arthroplasty and hip resurfacing patients (Enseki, Martin et al. 2010).

Habitually, health care professionals recommend rehabilitation with physiotherapy, consisting generally of exercises aiming to strengthen hip muscles, restore hip ROM, and develop balance, coordination and proprioception (Enseki, Martin et al. 2010; Grotle, Garratt et al. 2010; Liebs, Herzberg et al. 2010). Emphasis is on high intensity rehabilitation with a time-dependent progression. Patients are encouraged to start physiotherapy soon after surgery (Lavigne, Parvizi et al. 2004); as early as the first day of recovery (Herck, Vanhaecht et al. 2010). Group or individual sessions, ranging from two to four hours daily, are customary. Mobility is progressively stimulated, targeting improvements in activities of daily living, such as transfers, walking, sitting and standing, and stair climbing (Grotle, Garratt et al. 2010; Liebs, Herzberg et al. 2010). Specifically, most hip rehabilitation programs include low impact exercises that isolate specific muscle groups, such as isometric hip and knee extensions, active hip abduction and flexion as well as other gluteus, hamstring and quadriceps sets (Strickland, Fares et al. 1992; Herck, Vanhaecht et al. 2010). Others have promoted the use of bicycling (Lavigne, Parvizi et al. 2004; Liebs, Herzberg et al. 2010), swimming (Lavigne, Parvizi et al. 2004), pilates (Levine, Kaplanek et al. 2009) and specialized aquatic programs (Rahmann, Brauer et al. 2009) as effective ways of achieving considerable and clinically important improvements in patients' early and late recovery following hip surgery. Importantly, the level of compliance to rehabilitation has been shown to influence postoperative outcomes; patients who were more committed to their therapy returned to higher levels of functionality and satisfaction (Marker, Seyler et al. 2010).

Outcome Measurements

Qualitative Methods

There exist several validated questionnaires – considered to be reliable and reproducible – that can be used to qualitatively measure the outcome of hip surgeries. Notably, the Western Ontario and McMaster Universities Osteoarthritis Index (WOMAC) is a disease-specific questionnaire originally created to assess pain, stiffness and function of the arthritic knee or hip and is often used to evaluate FAI affected hips (Bellamy, Buchanan et al. 1988). Similarly, the Harris Hip Score can be used to evaluate hip function, pain, ROM and absence of deformity (Harris 1969). Other questionnaires such as the Short Form-36 Health Survey (SF-36) (Ware Jr and Sherbourne 1992), the Merle d'Aubigné Score (d'Aubigné and Postel 1954), the Nonarthritic Hip Score (NAHS) (Christensen, Althausen et al. 2003) and the UCLA Activity Score (Amstutz, Thomas et al. 1984) are also occasionally used to assess hip function, mobility, pain and overall sense of well-being.

Several studies have used the aforementioned questionnaires to measure the preoperative and postoperative quality of life of patients having undergone cam FAI surgery. Of interest, improvements in the Harris Hip Score and WOMAC index have been reported following surgery using an open approach (Peters and Erickson 2006; Beaulé, LeDuff et al. 2007), an arthroscopic approach (Ilizaliturri Jr, Orozco-Rodriguez et al. 2008; Byrd and Jones 2009) and a combined arthroscopic and open approach (Lincoln, Johnston et al. 2009).

Interestingly, Callaghan and colleagues (1990) evaluated five frequently used rating systems to assess results of patients who had undergone hip surgery. These self-assessed questionnaires were found to have no uniformity of results between ratings or between results and patient impressions. Some studies have also advocated that subjective perception of function, measured by questionnaires, does not concord with objective results

(Lindemann, Becker et al. 2006; Thorborg, Roos et al. 2009). Moreover, Thorborg et al. (2009) demonstrated that there exists a lack of valid and reliable questionnaires assessing groin pain. This was deemed problematic when assessing FAI patients since groin symptoms are frequently reported while hip symptoms are not. Likewise, Christensen et al. (2003) stated that most questionnaires are not specific or concise enough for application to young and active patients with hip pathologies. Seeing as FAI is prevalent in young active adults and is often associated with groin pain, it is possible that these questionnaires do not accurately measure the outcome of FAI surgery (Thorborg, Roos et al. 2009). Quantitative assessments of surgical outcomes are therefore needed to acquire objective information that can be universally comparable (Lindemann, Becker et al. 2006).

Quantitative Methods

There exist several methods in the field of biomechanics to evaluate joint function and performance. Distinctly, kinematic and kinetic measurements are frequently utilized in the evaluation of asymptomatic and symptomatic joints.

Modern techniques to measure lower-extremity joint kinematics have been well defined and are often used to examine gait temporal parameters such as cadence, stride length and duration of stance and swing phases. Equally, segment and joint velocities, accelerations, ROM and angular displacements can be obtained for various movements (Kadaba, Ramakrishnan et al. 1990; DavisIII, Ounpuu et al. 1991; Miki, Sugano et al. 2004).

Kinetic studies also provide valuable information regarding joint muscle forces, moments and powers. Typically, the principles of inverse dynamics – based on Newtonian mechanics and Euler equations of motion – are used to combine force platform and

kinematic data to calculate the abovementioned kinetic variables. These methods have been well established elsewhere (DavisIII, Ounpuu et al. 1991; Winter 2005).

Activities of Daily Living

This study examined the hip, knee, ankle and pelvic kinematics, as well as the hip, knee and ankle kinetics during walking and squatting. Seeing as gait is the most common repetitive movement performed by humans (Winter 1983), it was judged important to investigate the effects of FAI on hip function during such an activity. Likewise, maximal depth squatting is a controlled movement that requires a great amount of hip and pelvic motion, approaching the limits of hip motion in FAI patients. Although not a common daily activity on its own, squatting is a constituent of various tasks performed on a daily basis by most individuals. Therefore, it was judged appropriate to evaluate hip function during such tasks in patients having undergone cam FAI surgery to ascertain if the surgical intervention was successful in restoring normal lower-extremity joint biomechanics.

Walking

Lower-extremity joint kinematics and kinetics during level gait have long been a subject of interest in biomechanics. Specifically, non-pathologic gait has been extensively investigated (Crowinshield, Brand et al. 1978; Kadaba, Ramakrishnan et al. 1989; Kadaba, Ramakrishnan et al. 1990; Eng and Winter 1995; Mills and Barrett 2001; Möckel, Perka et al. 2003). It has been noted that lower-extremity joint biomechanics during gait vary as a result of gender (Kerrigan, Todd et al. 1998) and walking speed (Crowinshield, Brand et al. 1978; Mann and Hagy 1980; Kadaba, Ramakrishnan et al. 1989; Möckel, Perka et al. 2003; Bejek, Paroczai et al. 2006), underlining the importance of controlling for such variables to obtain valid and reliable data. For instance, lower-extremity joint angles in the sagittal plane

(Crowinshield, Brand et al. 1978; Mann and Hagy 1980; Bejek, Paroczai et al. 2006) as well as resultant hip forces and moments (Crowinshield, Brand et al. 1978) have been shown to augment with increasing walking speeds. Nevertheless, Kadaba et al. (1989) demonstrated that gait variables were very repeatable when participants walked at their natural or preferred speed, suggesting that a natural walking pace should be encouraged during gait analysis.

Normal peak hip angles and ROM during gait have been formerly established. Particularly, at natural walking speeds, peak hip angles have been shown to range from 20-30° in flexion and 5-11° in extension (Mann and Hagy 1980; Kadaba, Ramakrishnan et al. 1990; Judge, DavisIII et al. 1996; Kerrigan, Todd et al. 1998; Möckel, Perka et al. 2003; Winter 2005; Bejek, Paroczai et al. 2006). In the frontal plane, peak hip angular displacements are approximately 5° in abduction and 5° in adduction (Kadaba, Ramakrishnan et al. 1990; Judge, DavisIII et al. 1996), while in the transverse plane, peak hip angles are roughly 7° in internal rotation and 1° in external rotation (Kadaba, Ramakrishnan et al. 1990; Judge, DavisIII et al. 1996). Likewise, several studies have determined the 3-D pelvic ROM during level gait of healthy individuals (Kadaba, Ramakrishnan et al. 1990; Judge, DavisIII et al. 1996; Bejek, Paroczai et al. 2006). Normal pelvic angles were found to range from 3-16° in the sagittal plane (Kadaba, Ramakrishnan et al. 1990; Judge, DavisIII et al. 1996; Bejek, Paroczai et al. 2006), 2-9° in the frontal plane (Kadaba, Ramakrishnan et al. 1990; Judge, DavisIII et al. 1996; Bejek, Paroczai et al. 2006) and 3-9° in the transverse plane (Kadaba, Ramakrishnan et al. 1990; Judge, DavisIII et al. 1996; Bejek, Paroczai et al. 2006).

Healthy lower-extremity joint kinetics during level walking have also been widely investigated (Eng and Winter 1995; Kerrigan, Todd et al. 1998; Kirkwood, Culham et al. 1999; Winter 2005). Of note, peak hip moments during gait have been shown to range from

0.4-1.3 Nm/kg in flexion, 0.6-1.1 Nm/kg in extension, 0.8-1.3 Nm/kg in abduction, 0.1-0.2 Nm/kg in adduction, 0.1-0.2 Nm/kg in internal rotation and 0.1-0.2 Nm/kg in external rotation (Eng and Winter 1995; Kerrigan, Todd et al. 1998; Kirkwood, Culham et al. 1999).

Concerning FAI, there is only one known study that compared gait kinematics and kinetics of FAI patients and healthy control subjects. Kennedy et al. (2009b) compared a group of 17 patients with unilateral cam FAI to a control group of 14 healthy participants matched for age, sex and body mass index. The FAI group was found to have smaller peak hip abduction angles as well as reduced hip and pelvic frontal plane ROM during level gait compared to the control group. No differences in gait kinetics were noted between the two groups (Kennedy, Lamontagne et al. 2009b).

Interestingly, Rab (1999) evaluated pathological gait as a result of slipped capital femoral epiphysis (SCFE), an abnormal hip morphology closely related to cam FAI. Using a computer simulated motion analysis of walking, hips with SCFE demonstrated increased hip adduction and external rotation as well as decreased hip flexion during gait. It is important to note, however, that this study only accounted for bone tissue, neglecting soft tissue.

To our knowledge, no research has been conducted on lower-extremity joint mechanics during gait in patients having undergone surgery for cam impingement.

Squatting

Squatting is a common maneuver that requires a large ROM of the lower-extremity joints. The normal hip, knee, ankle and pelvic biomechanics during loaded and unloaded squatting at various speeds have been well assessed (Flanagan, Salem et al. 2003; Hemmerich, Brown et al. 2006; Manabe, Shimada et al. 2007; Hwang, Kim et al. 2009).

Specifically, normal hip angles during squatting have been shown to range from 90-130° in flexion (Singh and Wason 1988; Mulholland and Wyss 2001; Flanagan, Salem et al. 2003; Hemmerich, Brown et al. 2006; Manabe, Shimada et al. 2007), 10-30° in abduction (Singh and Wason 1988; Mulholland and Wyss 2001; Hemmerich, Brown et al. 2006) and 5-36° in external rotation (Singh and Wason 1988; Mulholland and Wyss 2001; Hemmerich, Brown et al. 2006).

Equally, normal peak hip moments in the sagittal plane have been shown to range from 0.73-1.22 Nm/kg and 0.74-1.72 Nm/kg during the descent and ascent phases of the squat manoeuvre, respectively (Flanagan, Salem et al. 2003; Manabe, Shimada et al. 2007).

Only one study was found examining hip and pelvic joint kinematics of patients with cam FAI. Lamontagne et al. (2009) compared hip and pelvic angles during squatting of 15 patients with cam impingement and 11 healthy control subjects matched for age, sex and body mass index. The FAI group had a reduced sagittal plane pelvic ROM ($14.7^{\circ} \pm 8.4^{\circ}$) compared to the control group ($24.2^{\circ} \pm 6.8^{\circ}$). Conversely, no differences in the 3-D hip angles at maximal squat depth were noted between the two groups. Furthermore, the control group was reported to squat to a greater depth of $32.3 \pm 6.8\%$ of leg length compared to $45.1 \pm 12.5\%$ for the cam impingement group.

To our knowledge, no study has evaluated the lower-extremity joint kinetics or compared preoperative and postoperative lower-extremity joint biomechanics of FAI patients during squatting.

METHODOLOGY

The present study consisted of the second phase of a larger research project. In the first phase of the study, data were collected during level walking and maximal depth squatting for preoperative cam FAI patients and healthy control subjects matched for age, sex and body mass index. In the current phase of the study, a group of patients having undergone corrective surgery for cam FAI was tested. As a result, the present study compared three groups (preoperative cam FAI, postoperative cam FAI and control groups) during level walking. Likewise, a repeated-measures design was used to compare the preoperative and postoperative cam FAI groups during maximal depth squatting.

Participants

In the first phase of the study, seventeen participants with unilateral symptomatic cam FAI were compared with fourteen healthy control subjects matched for age, sex and body mass index. In the current phase of the study, ten of the seventeen participants with cam FAI returned for postoperative testing. The seven cam FAI participants who did not return for postoperative testing were excluded for the following reasons: four declined to participate, one suffered a spinal disc hernia, one had a hip resurfacing and one underwent surgery for severe leg pain, which was unrelated to FAI. Also, data from thirteen of the fourteen control subjects were used for analysis. Therefore, ten cam FAI patients were compared preoperatively and postoperatively, and with thirteen healthy control subjects. Cam FAI patients were recruited through the Ottawa Hospital. Participants were selected preoperatively if they were between eighteen and fifty years of age, had a positive impingement test, and a visible cam deformity on anteroposterior and Dunn view radiographs (Meyer, Beck et al. 2006; Clohisy, Carlisle et al. 2008), which were

administered by radiologists of the Ottawa Hospital. Each participant also had an alpha angle greater than 50° , which is a diagnostic feature of cam FAI (Nötzli, Wyss et al. 2002). FAI patients were excluded from the study if they had hip osteoarthritis identified by substantial joint space narrowing on radiographs of the hip, a symptomatic contralateral hip, or if the FAI morphology was not purely of a cam type.

All FAI patients underwent corrective surgery for cam FAI, performed by the same surgeon using an open or combined technique involving the dislocation of the hip and debridement of the femoral head-neck junction. Postoperatively, FAI patients followed a standard rehabilitation program, as recommended by a healthcare professional. Postoperative testing of each participant occurred between eight and thirty-two months after surgery.

Prior to their involvement in the study, each participant provided their informed written consent, which was approved by the University of Ottawa Health Sciences and Science Research Ethics Board.

Data Collection Procedures

Motion Recordings

The 3-D kinematics of participants, as they performed various movements within the capture volume, were collected at 200 Hz using an infrared nine-camera high-speed motion analysis system (Vicon MX-13, Oxford Metrics, Oxford, UK) with 45 associated retro-reflective markers.

A two-part calibration of the Vicon system was performed. First, a dynamic calibration was executed. This involved waiving a T-shaped wand (240mm) equipped with three 14mm retro-reflective markers in a 5m x 3m x 2m volume. This procedure was fulfilled when all MX-13 cameras had captured a minimum of 4000 frames in which all three wand-

markers were visible. This calibration procedure was used to determine the lens properties of each MX camera as well as their position and orientation with respect to one another.

Next, a static calibration was performed to define the origin of the global coordinate system. This consisted of placing and levelling a calibration object – an L-shaped frame (ErgoCal 14mm) equipped with four 14mm retro-reflective markers – amid the capture volume. The global origin and axes were set to correspond to the position and orientation of the calibration object.

Ground Reaction Forces

Ground reaction forces were recorded at 1,000 Hz during squatting and the stance phase of the gait cycle using two force platforms (Model FP4060-08, Bertec Corp., Columbus, OH, USA) that were embedded side-by-side in the floor, creating a level surface.

Experimental Protocol

Participants presented themselves upon availability at the University of Ottawa (200 Lees Avenue, room E020), for approximately two hours, for biomechanical analysis. They dressed in skin-tight shorts and short-sleeved shirt to minimize clothing artefact during motions trials. Various anthropometric measurements (i.e. mass, height, leg length, knee width, ankle width and tibia height) were obtained for each participant using a physician scale, a measuring tape and callipers. These values were entered into Nexus software (Vicon, Oxford Metrics, Oxford, UK) to define participant measurements and calculate joint centres. Additional participant information such as age, leg dominance, sport and physical activity habits, and previous lower-extremity injuries were noted. FAI participants also filled out the WOMAC questionnaire with respect to their affected hip (Bellamy, Buchanan et al. 1988).

Participants then executed a series of warm-up exercises – as demonstrated by the researcher – to properly stretch their hip flexors/extensors, abductors/adductors and rotators, and reduce the risk of injury. Then, participants performed a maximal sit and reach flexibility test which required them to sit on the ground with their legs fully extended, and extend their arms anteriorly as far as possible over a custom-made instrument (Model 01285A, Lafayette Instrument Company, IN, USA).

Retro-reflective markers were affixed onto various anatomical landmarks, according to the University of Ottawa Motion Analysis Model marker-set, which is a modified version of the Helen Hayes marker-set (Kadaba, Ramakrishnan et al. 1990) (Appendix A & B).

Afterwards the participants performed a static calibration trial, in which they stood in a neutral position with their feet shoulder-width apart and facing anteriorly and their legs straight. These static trials were used to calculate each participant's segment lengths and determine their neutral pelvic and lower-extremity joint angles.

Next, participants performed a series walking and squatting trials. Before each task, the researcher provided a demonstration and participants were given the chance to practise several times to reduce the effects of learning.

First, participants performed barefoot level walking trials during which they walked at a natural, self-selected pace (Crowinshield, Brand et al. 1978; Mann and Hagy 1980; Kadaba, Ramakrishnan et al. 1989; Möckel, Perka et al. 2003; Bejek, Paroczai et al. 2006) with their head up and looking forward as to not alter their gait (i.e. stride length and width) by targeting the force platform. Five successful trials, where the foot of the affected leg landed on the force platform, were executed. Trials were discarded and restarted if a gait alteration was noticed or if the designated foot did not fully land on the force platform.

Then, participants performed five maximal depth squats. A height-adjustable bench (Appendix C), set to 1/3 of the participant's tibial plateau height, was used as a maximal depth indicator and served as a means of injury prevention if participants lost their balance and fell backward during a trial. To perform the squat manoeuvre, participants stood in an upright position, approximately 10 cm in front of the bench which was placed behind the two force platforms. With one foot on each force platform, participants positioned their feet shoulder-width apart, parallel to each other and facing anteriorly. Then, with their arms extended anteriorly to improve balance and prevent their use for support, participants squatted at a self-selected and controlled pace until their buttocks reached the depth of the bench, and then ascended back to a standing position. If participants could not squat to the bench depth, they squatted to their lowest attainable depth. For a trial to be deemed successful, participants were required to keep their feet flat on the ground and maintain their centre of mass between their feet.

Data Processing Procedures

Kinematic Analysis

Three-dimensional hip, knee, ankle and pelvic angles of each participant were analyzed for the walking and squatting conditions. The cycle of interest for walking (gait cycle) was initiated with a foot strike on the force platform and ended with the subsequent ipsilateral foot strike on the ground. The cycle of interest for squatting was initiated with knee flexion from a standing position at the start of the descent phase and ended with full knee and hip extension at the end of the ascent phase.

The recorded 3-D marker trajectories were filtered using a Woltring filter (predicted mean square error value of 15 mm²) (Woltring 1986). The lower-extremities were modeled

as a rigid linked body, as previously described (Miki, Sugano et al. 2004). The kinematic model, consisting of the thigh, shank and foot segments of each lower-extremity, as well as the pelvis, was modified to include additional markers on the medial femoral epicondyles and medial malleoli to define the knee and ankle joint centres as the mid-point between the medial and lateral markers at each joint, respectively. The hip, knee and ankle joints were each assigned three rotational degrees of freedom (flexion-extension, abduction-adduction, internal-external rotation). The rotations at each of these joints were defined by an Euler angle convention (YXZ). Similarly, the pelvis was assigned three rotational degrees of freedom (i.e., pitch, obliquity and rotation, which were measured in the sagittal, frontal and transverse planes, respectively) relative to a global coordinate system. Joint angles were expressed in relation to each participant's neutral position as determined by a static trial.

Kinetic Analysis

The ground reaction forces and moments were filtered using a second order low-pass Butterworth filter (cut-off of 8 Hz). An inverse dynamics approach (Winter 2005) – which uses known forces and moments at the distal joint of a segment, in addition to the segment's motion and inertial properties to calculate the forces and moments at the proximal joint of the segment – was used to obtain weight-normalized hip, knee and ankle moments, and hip powers, the latter which was calculated as the resultant of the hip powers in all three planes.

The kinematic and kinetic variables acquired for the affected leg during the five walking and squatting trials were averaged for each preoperative and postoperative cam FAI participant. For each control subject, the variables obtained for both legs during the five walking and squatting trials were averaged. The kinematic and kinetic dependent variables of interest are displayed in Table 1 and Table 2, respectively.

Table 1. Kinematic dependent variables.

Condition	Joint/Segment	Variable
Walking	Pelvis	Minimum angle in all three planes
		Maximum angle in all three planes
		Range of motion in all three planes
	Hip	Minimum angle in all three planes
		Maximum angle in all three planes
		Range of motion in all three planes
	Knee	Minimum angle in the sagittal plane
		Maximum angle in the sagittal plane
		Range of motion in the sagittal plane
	Ankle	Minimum angle in the sagittal plane
		Maximum angle in the sagittal plane
		Range of motion in the sagittal plane
Squatting	Pelvis	Maximum angle in all three planes
		Angular value in all three planes at maximal depth
		Range of motion in all three planes
	Hip	Angular value in all three planes at maximal depth
	Knee	Angular value in all three planes at maximal depth
	Ankle	Angular value in all three planes at maximal depth
Other	Sum of all joint angles in the sagittal plane at maximal depth Maximal depth attained	

Table 2. Kinetic dependent variables.

Condition	Joint	Variable
Walking	Hip	Minimum moment in all three planes
		Maximum moment in all three planes
		Minimum power
		Maximum power
	Knee	Minimum moment in the sagittal plane
		Maximum moment in the sagittal plane
Ankle	Minimum moment in the sagittal plane	
	Maximum moment in the sagittal plane	
Squatting	Hip	Minimum moment in all three planes during descent
		Maximum moment in all three planes during descent
		Minimum moment in all three planes during ascent
		Maximum moment in all three planes during ascent

Statistical Analysis

All statistical tests were conducted using SPSS software version 15.0 (SPSS Inc., Chicago, Illinois, USA). Two distinct approaches were employed to conduct statistical analyses on the variables of interest for the walking and squatting conditions. For the walking condition, three groups (preoperative FAI, postoperative FAI and control groups) were included in the statistical tests, while a repeated-measures design was used for the squatting condition, comparing only the preoperative and postoperative FAI groups.

Specifically, a series of multivariate analyses of variance (MANOVAs) was performed to determine the presence of significant differences between the preoperative FAI and control groups and between the postoperative FAI and control groups with regard to the kinematic and kinetic variables of interest, and the spatiotemporal parameters during level walking. Additionally, multiple repeated-measures MANOVAs were conducted to detect the presence of significant differences between the measurements of the preoperative and postoperative FAI groups. Seeing as several comparisons were made between the groups of interest, a Bonferroni correction was used to adjust the alpha values used to determine statistical significance, controlling the probability of false positives (Feise 2002). For all kinematic variables, the alpha value was adjusted to $\alpha = 0.017$ ($p < 0.05/3$) since three comparisons were made in each plane (minimum value, maximum value, ROM). For all kinetic variables, the alpha value was adjusted to $\alpha = 0.025$ ($p < 0.05/2$) since two comparisons were made in each plane (minimum value, maximum value).

Multiple repeated-measures multivariate analyses of variance (MANOVAs) were conducted to determine the presence of significant differences between the preoperative and postoperative FAI groups, with regard to the kinematic and kinetic variables of interest, and the spatiotemporal parameters during maximal depth squatting. The alpha value was set at

0.05 for all statistical analyses regarding the lower-extremity joint angles. For all statistical analyses concerning pelvic angular displacements, a Bonferroni correction was used to adjust the alpha value to 0.017 ($p < 0.05/3$) because three comparisons were made in each plane (maximum value, value at maximal squat depth and ROM) (Feise 2002). Likewise, the alpha value was adjusted to $\alpha = 0.013$ ($p < 0.05/4$) for all kinetic variables since four comparisons were made in each plane (minimum value during descent, maximum value during descent, minimum value during ascent, maximum value during ascent).

FIRST ARTICLE

*The Effects of Cam Femoroacetabular Impingement
Corrective Surgery on Lower-Extremity Gait Biomechanics*

Nicholas Brisson^a, Mario Lamontagne^{ab}, Matthew J. Kennedy^a and Paul E. Beaulé^c

^a School of Human Kinetics, University of Ottawa, Canada

^b Department of Mechanical Engineering, University of Ottawa, Canada

^c Division of Orthopaedic Surgery, The Ottawa Hospital, Canada

Introduction

Cam femoroacetabular impingement (FAI), the result of abutment between an aspherical proximal femur and the acetabular rim during hip movement (Ganz, Parvizi et al. 2003; Beck, Leunig et al. 2004b), is a well documented source of hip pain in young active adults (Wisniewski and Grogg 2006; Beaulé, LeDuff et al. 2007). This hip pathology causes repetitive low-impact loading at the site of impingement, leading to labral and chondral defects (Eijer, Myers et al. 2001; Ganz, Parvizi et al. 2003; Lavigne, Parvizi et al. 2004; Tanzer and Noiseux 2004; Beck, Kalhor et al. 2005; Leunig, Beck et al. 2005; Philippon and Schenker 2006; Tannast, Goricki et al. 2008), which may progress into hip osteoarthritis (Murray 1965; Stulberg, Cordell et al. 1975; Harris 1986; Ito, Minka-II et al. 2001; Ganz, Parvizi et al. 2003; Beck, Leunig et al. 2004b; Leunig, Beck et al. 2005). Most often, symptoms of FAI arise during movements that solicit the extremes of range of motion (ROM) of the hip such as squatting (Philippon and Schenker 2006; Laude, Boyer et al. 2007), but have also been reported during activities requiring normal ROM of the hip as seen during prolonged walking (Ganz, Parvizi et al. 2003; Leunig, Beck et al. 2005). Given that FAI mainly affects young active adults, conservative treatment plans are usually not favoured as they require radical lifestyle changes and restrictions in physical activity. As a result, FAI is primarily corrected by means of surgery (Guanche and Bare 2006). Several surgical approaches, such as the open (Ganz, Gill et al. 2001; Lavigne, Parvizi et al. 2004), arthroscopic (Sampson 2005; Weiland and Philippon 2005; Guanche and Bare 2006) and combined techniques (Clohisy and McClure 2005; Barton, Banga et al. 2009; Lincoln, Johnston et al. 2009), are available to restore a normal femoral head-neck offset in FAI patients.

Numerous qualitative studies have used validated questionnaires such as the Harris Hip Score (Harris 1969) and the Western Ontario and McMaster Universities Osteoarthritis Index (WOMAC) (Bellamy, Buchanan et al. 1988) to deem FAI corrective surgery successful in reducing or eliminating hip pain (Peters and Erickson 2006; Beaulé, LeDuff et al. 2007; Lincoln, Johnston et al. 2009). Likewise, some studies have reported improvements in postoperative hip passive ROM of FAI patients (Stähelin, Stähelin et al. 2008; Lincoln, Johnston et al. 2009). A few studies have investigated the 3-D kinematic and kinetic differences between healthy control subjects and individuals with FAI. These investigations demonstrated that the FAI group had restricted hip (Kennedy, Lamontagne et al. 2009a) and pelvic (Lamontagne, Kennedy et al. 2009) mobility during tasks requiring large lower-extremity joint ROM as well as reduced hip and pelvic motion in the frontal plane during level gait (Kennedy, Lamontagne et al. 2009b) compared to the control group. Recently, two studies have compared the preoperative and postoperative lower-extremity joint kinematics of FAI patients (Lamontagne, Brisson et al. 2011; Rylander, Shu et al. 2011) Specifically, Rylander et al. (2011) assessed eleven FAI patients during level gait, within one month before arthroscopic surgery and again one year postoperatively. They observed an increase in postoperative hip sagittal plane ROM on the affected side, primarily due to an increase in maximum flexion angle.

To our knowledge, no study has used motion analysis and ground reaction forces to compare the lower-extremity joint biomechanics during level walking of individuals with cam FAI before and after corrective surgery using an open or combined technique. Seeing as gait is the most common repetitive movement performed by humans (Winter 1983), it is important to investigate the effects of FAI on hip joint function during such an activity. Understanding the effects of FAI on hip function during walking, before and after corrective

surgery, is essential in confirming that surgical intervention effectively restores more normal biomechanics of the hip. Such an analysis may provide valuable insight that could be used to improve surgical techniques and develop rehabilitation programs for the treatment of FAI.

Consequently, the purpose of this study was to determine the effects of cam FAI corrective surgery on the affected lower-extremity joint mechanics during level gait by comparing the three-dimensional (3-D) angular displacements of the hip, knee, ankle and pelvis, as well as the moments and powers at the hip, knee and ankle of preoperative and postoperative FAI groups to those of a healthy control group. A secondary objective was to verify if the quantitative biomechanical data concurred with the qualitative results obtained with the WOMAC questionnaire. We hypothesized that there would be no significant differences between the postoperative cam FAI group and the control group with regard to the kinematic variables; suggesting that corrective surgery effectively restored the normal hip biomechanics of FAI patients. Due to the lack of existing data on FAI lower-extremity joint moments and powers, no hypotheses were founded regarding the kinetic variables. Moreover, we hypothesized that the overall postoperative WOMAC scores would improve, reflecting reductions in hip pain and stiffness, and an increase in hip function.

Methods

Participants

This study consisted of two phases. In the first phase, seventeen participants with unilateral symptomatic cam FAI were compared to fourteen healthy control subjects matched for age, sex and body mass index (Kennedy, Lamontagne et al. 2009b). In the current phase of the study (second phase), ten of the seventeen participants with cam FAI returned for postoperative testing. Also, data from thirteen of the fourteen control subjects were used for

analysis. Therefore, ten cam FAI patients were compared preoperatively and postoperatively, and with thirteen control subjects (Table 3). FAI patients were between eighteen and fifty years of age, had a positive impingement test, a visible cam deformity on anteroposterior and Dunn view radiographs (Meyer, Beck et al. 2006; Clohisy, Carlisle et al. 2008), and an alpha angle greater than 50 degrees. Patients were excluded from the study if they had hip osteoarthritis identified by substantial joint space narrowing on hip radiographs, a symptomatic contralateral hip, or if the FAI deformity was not purely of a cam type.

FAI patients were tested preoperatively and postoperatively. All patients were operated by the same surgeon using an open or combined approach, which involved the dislocation of the hip and debridement of the proximal femur (Ganz, Gill et al. 2001; Clohisy and McClure 2005). Depending on the surgical approach utilized, some hip joint muscles were incised or detached to allow greater exposure of the impingement site. Postoperative testing occurred upon participant availability, between eight and thirty-two months after surgery. Prior to their involvement in the study, each participant provided their informed written consent, which was approved by the institution's research ethics board.

Table 3. Descriptive characteristics of the control (CON), preoperative cam FAI (PRE) and postoperative cam FAI (POST) participants. Values are expressed as mean \pm standard deviation.

Group	Male/Female (n)	Age (years)	BMI (kg/m ²)	WOMAC Pain†	WOMAC Stiffness	WOMAC Function
CON	8/5	34.2 \pm 9.9	23.1 \pm 2.4	N/A	N/A	N/A
PRE	7/3	29.9 \pm 7.2	23.3 \pm 2.7	67.2 \pm 16.2	67.4 \pm 16.2	82.4 \pm 15.4
POST	7/3	32.3 \pm 7.2	24.8 \pm 3.1	80.6 \pm 14.7	65.9 \pm 18.5	84.6 \pm 17.6

† Significant difference ($p < 0.05$) between PRE and POST groups.

Instrumentation

Level walking 3-D kinematics were collected at 200 Hz using a nine-camera high-speed motion analysis system (Vicon MX, Los Angeles, California) with forty-five retro-

reflective markers affixed onto various anatomical landmarks, according to a modified Helen Hayes marker-set (Kadaba, Ramakrishnan et al. 1990). Ground reaction forces were also recorded at 1,000 Hz during the stance phase of the gait cycle using a force platform (Model FP4060-08, Bertec Corp., Columbus, OH, USA) which was embedded in the floor, creating a level walking surface.

Experimental Protocol

Participants changed into skin-tight shorts and short-sleeved shirt. Then, the retro-reflective markers were fixated onto the participants and various anthropometric measurements were taken. Afterwards, a static trial – consisting of the participants standing in a neutral position, with their feet shoulder-width apart, toes pointing anteriorly, and hip and knee joints fully extended – was recorded to calculate segment lengths and determine neutral pelvic and lower-extremity joint angles. To avoid any gait alteration caused by walking in a laboratory setting, participants were given the chance to execute several practice walking trials prior to data collection. Then, participants performed barefoot walking trials during which they were instructed to walk at a natural, self-selected pace and to keep their head up and look forward as to not alter their gait by targeting the force platform. Five successful trials, where the foot of the affected leg landed on the force platform, were executed. Trials were discarded if a gait alteration was noticed or if the designated foot did not fully land on the force platform.

Data Processing and Analysis

Lower-extremity kinematic and kinetic data for each participant were analyzed for five gait cycles. Each gait cycle was initiated with the foot strike of the affected leg on the force platform and ended with the subsequent ipsilateral foot strike on the ground.

The 3-D marker trajectories were filtered using a Woltring filter (predicted mean square error value of 15 mm^2) (Woltring 1986). The lower body was modeled as a rigid linked body as previously described (Miki, Sugano et al. 2004). The kinematic model, consisting of the thigh, shank and foot segments of each lower-extremity as well as the pelvis, was modified to include additional markers on the medial femoral epicondyles and medial malleoli to define the knee and ankle joint centres as the mid-point between the medial and lateral markers at each joint, respectively. Three rotational degrees of freedom (flexion-extension, abduction-adduction, internal-external rotation) were assigned to the hip, knee, and ankle joints. Rotations at each of these joints were defined by an Euler angle convention (YXZ). Similarly, three rotational degrees of freedom (pitch, obliquity and rotation, measured in the sagittal, frontal and transverse planes, respectively), relative to the global coordinate system, were assigned to the pelvis. Joint angles were expressed in reference to each participant's neutral position as determined by their static trial.

The ground reaction forces and moments were filtered using a second order low-pass Butterworth filter (cut-off frequency of 8 Hz). An inverse dynamics approach (Winter 2005) was used to obtain weight-normalized hip, knee and ankle moments as well as hip powers, the latter being calculated as the resultant of the hip powers in all three planes.

The extracted kinematic variables of interest were the peak angles and ROM of the pelvis and hip in all three planes as well as the sagittal plane peak angles and ROM of the knee and ankle during the gait cycle. Furthermore, peak hip moments in all three planes, peak hip powers, as well as peak knee and ankle moments in the sagittal plane were obtained for the stance phase of the gait cycle. The variables acquired for the affected leg during the five walking trials were averaged for each preoperative and postoperative cam FAI participant. For each control subject, the variables obtained from both legs during the five

walking trials were averaged. Several spatiotemporal parameters (i.e. stride length, stride time, walking speed and cadence) were also extracted and compared between groups.

Statistical Analysis

A series of multivariate analyses of variance (MANOVAs) was performed to determine the presence of significant differences between the preoperative FAI and control groups and between the postoperative FAI and control groups with regards to the aforementioned kinematic and kinetic variables of interest and the spatiotemporal parameters. Additionally, multiple repeated-measures MANOVAs were conducted to detect the presence of significant differences between the measurements of the preoperative and postoperative FAI groups.

Seeing as several comparisons were made between the groups of interest, a Bonferroni correction was used to adjust the alpha values used to determine statistical significance (Feise 2002). For all kinematic variables, the alpha value was adjusted to $\alpha = 0.017$ ($p < 0.05/3$) since three comparisons were made in each plane (minimum value, maximum value, ROM). For all kinetic variables, the alpha value was adjusted to $\alpha = 0.025$ ($p < 0.05/2$) since two comparisons were made in each plane (minimum value, maximum value). As a result of equipment malfunction, force platform data were not collected for two FAI participants. Therefore, preoperative and postoperative kinetic data for eight FAI patients were compared to those of thirteen control subjects.

Results

No significant differences were noted between the three groups with regards to the spatiotemporal parameters. Postoperatively, FAI patients scored significantly higher on the WOMAC questionnaire with respect to the hip pain score ($p = 0.035$). Conversely, no

significant differences were noted between the preoperative and postoperative WOMAC hip stiffness and function scores ($p > 0.05$) (Table 3).

Results from the MANOVAs on the kinematic variables revealed that both preoperative ($p = 0.016$) and postoperative ($p = 0.016$) FAI groups had significantly lower hip frontal plane ROM compared to the control group. Additionally, the postoperative FAI group had a significantly reduced hip sagittal plane ROM compared to the control group ($p = 0.013$). No significant differences were found between the preoperative FAI group and the control group and between the postoperative FAI group and control group with respect to knee, ankle and pelvis kinematics ($p > 0.017$).

Regarding the kinetic variables, results from the MANOVAs revealed that the postoperative FAI group produced smaller peak hip abduction ($p = 0.013$) and external rotation ($p < 0.001$) moments, and generated less peak hip power ($p = 0.004$) compared to the control group. The postoperative FAI group also produced smaller peak knee extension moments ($p = 0.002$) but greater peak knee flexion moments ($p < 0.001$) than the control group. No significant differences in ankle kinetics were found between the preoperative FAI group and the control group and between the postoperative FAI group and control group ($p > 0.025$) during level gait.

Results from the repeated-measures MANOVAs revealed no significant differences between the preoperative and postoperative FAI groups regarding all kinematic ($p > 0.017$) and kinetic ($p > 0.025$) variables during level walking.

For each group, the sagittal plane hip angles are shown in Figure 1, while the frontal plane hip angles and moments are depicted in Figure 2 and Figure 3, respectively. The means and standard deviations of the variables found to be statistically significantly different between the control, preoperative FAI and postoperative FAI groups are shown in Table 4.

Table 4. Kinematic and kinetic variables found to be statistically significantly different between the control (CON), preoperative FAI (PRE) and postoperative FAI (POST) participants. Values are expressed as mean \pm standard deviation.

Variables	CON	PRE	POST
Angles (°)			
Hip Adduction-Abduction ROM*·**	17.8 \pm 2.9	14.3 \pm 2.6	14.3 \pm 2.7
Hip Flexion-Extension ROM**	51.5 \pm 2.7	47.4 \pm 3.6	46.8 \pm 4.6
Moments (Nm/kg)			
Hip Peak Abduction**	-0.79 \pm 0.16	-0.68 \pm 0.11	-0.61 \pm 0.07
Hip Peak External Rotation**	0.19 \pm 0.07	0.14 \pm 0.03	0.08 \pm 0.04
Knee Peak Flexion**	0.28 \pm 0.07	0.35 \pm 0.03	0.40 \pm 0.08
Knee Peak Extension**	-0.94 \pm 0.27	-0.73 \pm 0.20	-0.55 \pm 0.14
Power (W/kg)			
Hip Peak Generation**	1.65 \pm 0.43	1.45 \pm 0.21	1.07 \pm 0.18

For all variables displayed: $p \leq 0.017$ for angles; $p \leq 0.025$ for moments and powers.

* Significant difference between CON and PRE groups.

** Significant difference between CON and POST groups.

Discussion

The primary objective of this study was to examine the effects of cam FAI corrective surgery on the affected lower-extremity joint kinematics and kinetics of FAI patients during level walking at a self-selected pace.

Postoperative WOMAC scores showed a marked improvement of 13.4 points with respect to hip pain following surgery. Conversely, no significant differences were found between the preoperative and postoperative WOMAC hip stiffness, function and overall scores, contradicting our hypotheses. The use of preoperative and postoperative pain medication was not controlled in this study. This may have affected the pain scores observed by the WOMAC questionnaire.

The first phase of this study (Kennedy, Lamontagne et al. 2009b) compared the level gait kinematics and kinetics of seventeen preoperative cam FAI patients and fourteen healthy control subjects. The FAI group was found to have a significantly lower peak hip abduction angle and reduced hip and pelvic frontal plane ROM compared to the control group. In the

present investigation, seven of the seventeen preoperative cam FAI patients and thirteen of the fourteen control subjects from the first phase, with the addition of three FAI patients who were not previously included, were compared. With somewhat modified samples, results revealed that the preoperative FAI group had a significantly reduced hip frontal plane ROM by 3.5° compared to the control group, which was in agreement with the findings from the previous phase (Kennedy, Lamontagne et al. 2009b). Although no other statistically significant differences were found between the abovementioned groups, the preoperative FAI group showed a trend towards a significantly diminished hip sagittal plane ROM ($p = 0.030$), as previously observed in the first phase (Kennedy, Lamontagne et al. 2009b). These subtle statistical differences between the preoperative FAI and control groups are likely the result of a reduced sample size in the current phase of the study.

The present study quantitatively compared the gait kinematics and kinetics of healthy control participants and cam FAI patients before and after surgery using an open or combined technique. Despite encouraging results in pain reduction as noted by the WOMAC questionnaire, contrarily to our hypotheses, it was determined that the gait mechanics of FAI patients did not return to normal following surgery.

Kinematic results revealed that the hip frontal plane ROM of FAI patients during level gait remained unchanged following surgery. As a result, both preoperative and postoperative FAI groups exhibited a significantly smaller hip frontal plane ROM, by 3.5° , compared to the control group (Figure 2). Moreover, the postoperative hip sagittal plane ROM diminished by 0.6° compared to the preoperative measurements, which was enough to convert the statistical trend found between preoperative FAI and control groups to a statistically significant reduction of 4.7° for the postoperative FAI group compared to the control group (Figure 1). Interestingly, both the reduced hip frontal and sagittal plane ROM

observed postoperatively resulted primarily from reductions in hip adduction and flexion angles, respectively, rather than from reductions in hip abduction and extension angles as seen preoperatively. The hip sagittal plane kinematic results of the present study do not concord with those of Rylander et al. (2011) who observed postoperative increases of 2.8° in hip peak flexion angle and 3.1° in hip sagittal plane ROM during level gait. Likewise, contrarily to Rylander et al. (2011), the current study did not observe abnormal reversals (second-order change in the slope) in any of the hip flexion-extension curves of the preoperative and postoperative FAI patients.

Previous studies have compared the passive ROM of the hip in patients with cam FAI before and after surgery and noted marked postoperative increases in hip flexion and internal rotation angles (Stähelin, Stähelin et al. 2008; Lincoln, Johnston et al. 2009). However, these studies evaluated the maximal passive angular displacements of the hip. Since the hip solicits only about 25% of its maximal dynamic ROM in the frontal plane and 35% in the sagittal plane during gait (Kennedy, Lamontagne et al. 2009a; Kennedy, Lamontagne et al. 2009b), it is safe to assume that the smaller hip angular displacements of FAI patients observed in this study are not the result of a femoral or acetabular mechanical restriction occurring at the extremes of ROM of the hip. Rather, reductions in hip mobility are thought to result from a joint stabilization strategy adopted by FAI patients to counteract hip muscular deficiencies (Beaulieu, Lamontagne et al. 2010); a speculation which may be supported by the kinetic data presented below.

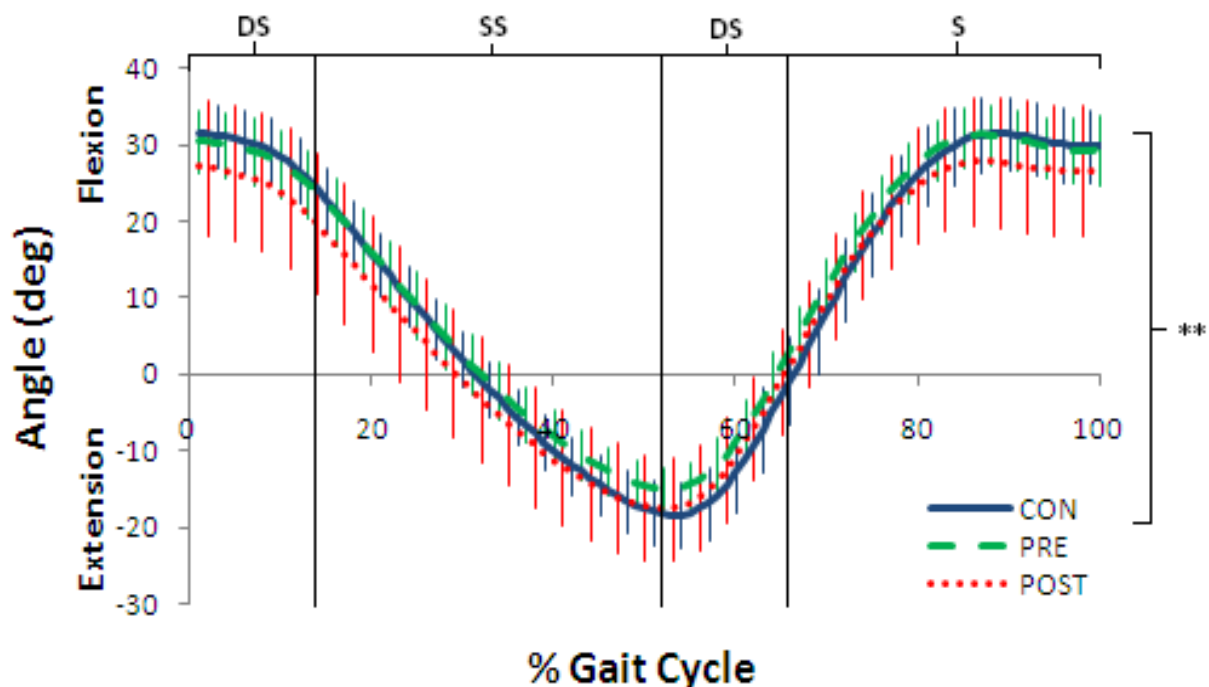


Figure 1. Average sagittal plane hip angles during level walking, time-normalized to the gait cycle. Hash marks represent the standard deviations. The double asterisks (**) represent a statistically significant difference between the healthy control (CON) and postoperative cam FAI (POST) groups. DS = double-limb stance; SS = single-limb stance; S = swing phase.

Of note, the preoperative FAI group produced smaller peak hip abduction and external rotation moments compared to the control group. However, these differences were not statistically significant. The postoperative FAI group produced even smaller peak hip abduction and external rotation moments than that preoperatively, differing significantly from that of the control group. Both peak hip abduction and external rotation moments occurred near the time of transfer from double-limb stance to single-limb stance onto the affected limb (Figure 3). It has been proposed that, at this time, hip surgery patients adopted a pelvic stabilization technique, reducing their hip motion in the frontal plane (i.e. peak adduction angle), allowing them to produce a smaller hip abduction moment – and perhaps a smaller hip external rotation moment – to counteract an opposing moment produced by their centre of mass (Beaulieu, Lamontagne et al. 2010).

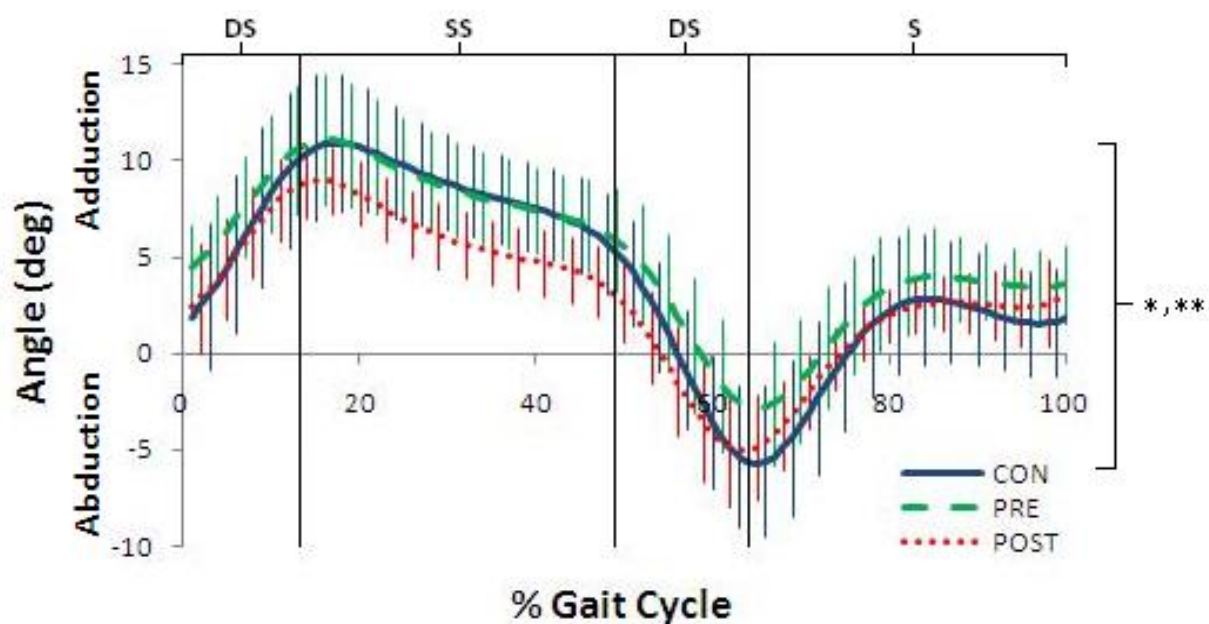


Figure 2. Average frontal plane hip angles during level walking, time-normalized to the gait cycle. Hash marks represent the standard deviations. The single asterisk (*) represents a statistically significant difference between the healthy control (CON) and preoperative cam FAI (PRE) groups while the double asterisks (**) represent a statistically significant difference between the CON and postoperative cam FAI (POST) groups. DS = double-limb stance; SS = single-limb stance; S = swing phase.

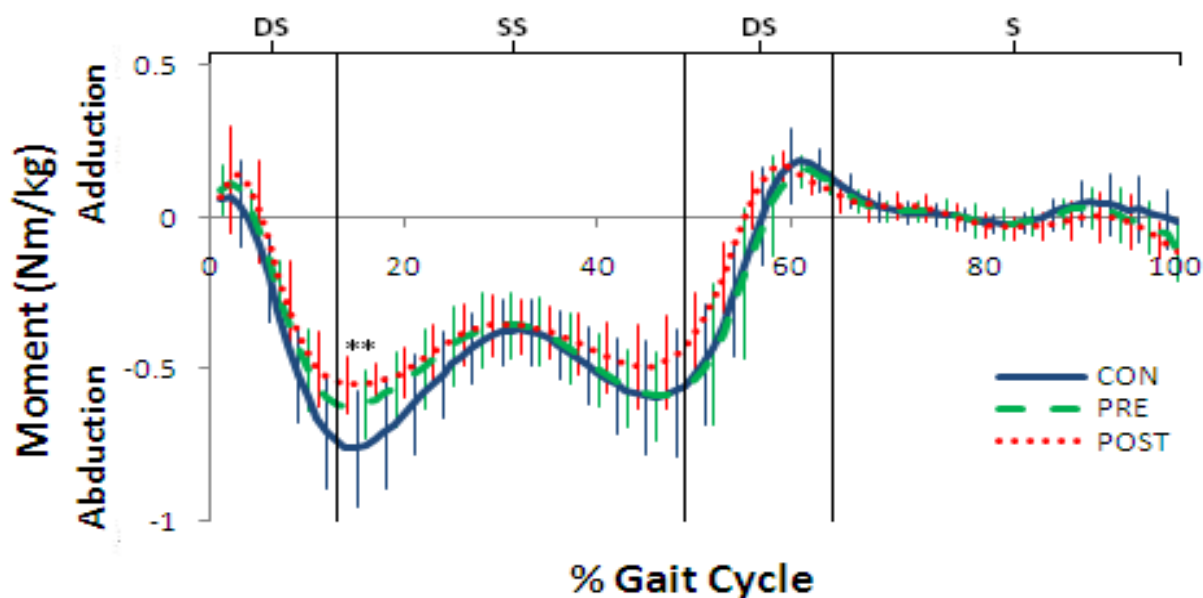


Figure 3. Average frontal plane hip moments of force during level walking, time-normalized to the gait cycle. Hash marks represent the standard deviations. The double asterisks (**) represent a statistically significant difference between the healthy control (CON) and postoperative cam FAI (POST) groups. DS = double-limb stance; SS = single-limb stance; S = swing phase.

Two hypotheses related to hip muscular deficiencies are proposed to explain the gait pattern modifications observed in FAI patients. Firstly, as previously underlined by Beaulieu et al. (2010), it is possible that preoperative hip surgery patients (e.g. preoperative FAI patients) adopted modified gait patterns in order to reduce hip muscle contractions, loading and pain, resulting in muscular disuse and atrophy. This theory could explain the slight kinetic and kinematic differences observed between preoperative FAI patients and healthy control subjects. Secondly, postoperative discrepancies in hip mechanics may have been caused by the surgery. Of interest, similar frontal plane gait pattern alterations have been noted in patients having undergone total hip arthroplasty – a surgical technique which closely resembles that used to treat FAI patients – and have been proposed to result from weakened hip abductors, postoperatively (Vogt, Banzer et al. 2004; Foucher, Hurwitz et al. 2007). In the present study, ten FAI patients were operated; four using an open approach and six using a combined approach. The open technique required incision of the iliotibial band and splitting of the gluteus maximus, while the combined technique occasionally necessitated the release of the reflected head of the rectus femoris. Seeing as the aforementioned soft tissues are major contributors to hip motion, their lack of complete recovery following surgical incision may well explain the postoperative biomechanical reductions in all three planes observed at the hip. The two aforementioned theories could explain the modified gait patterns of FAI patients. However, these speculations cannot be confirmed by the current investigation due to the lack of preoperative and postoperative lower-extremity electromyography data of FAI patients.

Some biomechanical differences at the knee, in the sagittal plane, were also observed between groups. Specifically, peak knee extension moments of the preoperative FAI group were smaller than that of the control group, but not found to be statistically significant.

Postoperatively, however, peak knee extension moments decreased even more, making them significantly smaller than that of the control group. Although it could be argued that the smaller postoperative peak knee extension moments may have been caused by the incision of the rectus femoris, the reasons for smaller preoperative peak knee extension moments remain unclear. Likewise, the explanation for increased peak knee flexion moments observed in FAI patients is beyond the scope of this study. Finally, the postoperative FAI group generated smaller peak hip powers compared to the control group; likely attributable to the combination of the aforementioned affected biomechanical variables.

Limitations of the current study included a large variability in postoperative test times, ranging from eight to thirty-two months. Some patients may have been at different stages of recovery. The relatively small sample size may have affected the exposure of statistical significant differences between the groups. Moreover, although two surgical approaches were used in this study, all FAI patients were combined into one postoperative group, not allowing the discrimination of the respective effects of each surgery on hip outcome measurements.

Conclusion

The present study demonstrated that the affected lower-extremity joint biomechanics of cam FAI patients during level walking did not completely return to normal following corrective surgery. Although cam FAI is considered to be caused mainly by an osseous deformation of the femoral head-neck junction, it seems that this hip pathology is associated with aberrant joint functions (i.e. muscle activation patterns, ligament tension and bone-on-bone contact) that have not yet been well identified. The differences that existed between the preoperative FAI and control groups, perhaps arising from modified gait patterns adopted,

were still present postoperatively. Moreover, additional reductions in lower-extremity joint mechanics were observed in postoperative FAI patients. These discrepancies may have resulted from the lack of complete restoration of hip muscle function following surgical incision. Future research, particularly with use of electromyography, is required to determine the reasons for which the normal lower-extremity gait mechanics of FAI patients are not restored postoperatively. Exposing these causes could aid in the development of better surgical techniques and rehabilitation programs, thus enhancing postoperative care.

References

- Barton, C., K. Banga, et al. (2009). "Anterior Hueter Approach in the Treatment of Femoro-Acetabular Impingement: Rationale and Technique." Orthopedic Clinics of North America **40**: 389-395.
- Beaulé, P. E., M. J. LeDuff, et al. (2007). "Quality of Life Following Femoral Head-Neck Osteochondroplasty for Femoroacetabular Impingement." The Journal of Bone & Joint Surgery **89-A**: 773-779.
- Beaulieu, M. L., M. Lamontagne, et al. (2010). "Lower limb biomechanics during gait do not return to normal following total hip arthroplasty." Gait & Posture **32**: 269-273.
- Beck, M., M. Kalhor, et al. (2005). "Hip morphology influences the pattern of damage to the acetabular cartilage." The Journal of Bone & Joint Surgery **87-B**(7): 1012-1018.
- Beck, M., M. Leunig, et al. (2004b). "Anterior Femoroacetabular Impingement. Part II. Midterm Results of Surgical Treatment." Clinical Orthopaedics **418**: 67-73.
- Bellamy, N., W. W. Buchanan, et al. (1988). "Validation study of WOMAC: A health status instrument for measuring clinically important patient relevant outcomes to antirheumatic drug therapy in patients with osteoarthritis of the hip or knee." The Journal of Rheumatology **15**: 1833-1840.
- Clohisy, J. C., J. C. Carlisle, et al. (2008). "A Systematic Approach to the Plain Radiographic Evaluation of the Young Adult Hip." The Journal of Bone & Joint Surgery **90-A**: 47-66.
- Clohisy, J. C. and J. T. McClure (2005). "Treatment of anterior femoroacetabular impingement with combined hip arthroscopy and limited anterior decompression." The Iowa Orthopaedic Journal **25**: 164-171.
- Eijer, H., S. R. Myers, et al. (2001). "Anterior Femoroacetabular Impingement After Femoral Neck Fractures." Journal of Orthopaedic Trauma **15**(7): 475-481.
- Foucher, K., D. Hurwitz, et al. (2007). "Preoperative gait adaptations persist one year after surgery in clinically well-functioning total hip replacement patients." Journal of Biomechanics **40**(15): 3432-3437.
- Ganz, R., T. J. Gill, et al. (2001). "Surgical dislocation of the adult hip." The Journal of Bone & Joint Surgery **83-B**(8): 1119-1124.

- Ganz, R., J. Parvizi, et al. (2003). "Femoroacetabular Impingement. A Cause for Osteoarthritis of the Hip." Clinical Orthopaedics and Related Research **417**: 112-120.
- Guanche, C. A. and A. A. Bare (2006). "Arthroscopic Treatment of Femoroacetabular Impingement." Arthroscopy: The Journal of Arthroscopic and Related Surgery **22**(1): 95-106.
- Harris, W. H. (1969). "Traumatic arthritis of the hip after dislocation and acetabular fractures: treatment by mold arthroplasty. An end-result study using a new method of result evaluation." The Journal of Bone and Joint Surgery **51-A**(4): 737-755.
- Harris, W. H. (1986). "Etiology of Osteoarthritis of the Hip." Clinical Orthopaedics and Related Research **213**: 20-33.
- Ito, K., M.-A. Minka-II, et al. (2001). "Femoroacetabular impingement and the cam-effect. A MRI-based quantitative anatomical study of the femoral head-neck offset." The Journal of Bone & Joint Surgery **83-B**(2): 171-176.
- Kadaba, M. P., H. K. Ramakrishnan, et al. (1990). "Measurement of Lower Extremity Kinematics During Level Walking." Journal of Orthopaedic Research **8**: 383-392.
- Kennedy, M. J., M. Lamontagne, et al. (2009a). "The effect of cam femoroacetabular impingement on hip maximal dynamic range of motion." Journal of Orthopedics **1**(1): 41-50.
- Kennedy, M. J., M. Lamontagne, et al. (2009b). "Femoroacetabular impingement alters hip and pelvic biomechanics during gait. Walking biomechanics of FAI." Gait & Posture **30**: 41-44.
- Lamontagne, M., N. Brisson, et al. (2011). "Preoperative and Postoperative Lower-Extremity Joint and Pelvic Kinematics During Maximal Squatting of Patients with Cam Femoro-Acetabular Impingement." The Journal of Bone and Joint Surgery (Am) **93**: 40-45.
- Lamontagne, M., M. J. Kennedy, et al. (2009). "The Effect of Cam FAI on Hip and Pelvic Motion during Maximum Squat." Clinical Orthopaedics and Related Research **467**: 645-650.
- Laude, F., T. Boyer, et al. (2007). "Anterior femoroacetabular impingement." Joint Bone Spine **74**: 127-132.
- Lavigne, M., J. Parvizi, et al. (2004). "Anterior Femoroacetabular Impingement. Part I. Techniques of Joint Preserving Surgery." Clinical Orthopaedics **418**: 61-66.
- Leunig, M., M. Beck, et al. (2005). "Femoroacetabular Impingement: Etiology and Surgical Concept." Operative Techniques in Orthopaedics **15**: 247-255.
- Lincoln, M., K. Johnston, et al. (2009). "Combined Arthroscopic and Modified Open Approach for Cam Femoroacetabular Impingement: A Preliminary Experience." Arthroscopy: The Journal of Arthroscopic and Related Surgery **25**(4): 392-399.
- Meyer, D. C., M. Beck, et al. (2006). "Comparison of Six Radiographic Projections to Assess Femoral Head/Neck Asphericity." Clinical Orthopaedics and Related Research **445**: 181-185.
- Miki, H., N. Sugano, et al. (2004). "Recovery of walking speed and symmetrical movement of the pelvis and lower extremity joints after unilateral THA." Journal of Biomechanics **37**: 443-455.
- Murray, R. O. (1965). "The aetiology of primary osteoarthritis of the hip." The British Journal of Radiology **38**: 810-824.

- Peters, C. L. and J. A. Erickson (2006). "Treatment of Femoro-Acetabular Impingement with Surgical Dislocation and Débridement in Young Adults." The Journal of Bone & Joint Surgery **88-A**(8): 1735-1741.
- Philippon, M. J. and M. L. Schenker (2006). "Arthroscopy for the Treatment of Femoroacetabular Impingement in the Athlete." Clinical Sports Medicine **25**: 299-308.
- Rylander, J. H., B. Shu, et al. (2011). "Preoperative and Postoperative Sagittal Plane Hip Kinematics in Patients With Femoroacetabular Impingement During Level Walking." The American Journal of Sports Medicine **39**(1): 36S-42S.
- Sampson, T. G. (2005). "Arthroscopic Treatment of Femoroacetabular Impingement." Techniques in Orthopaedics **20**(1): 56-62.
- Stähelin, L., T. Stähelin, et al. (2008). "Arthroscopic Offset Restoration in Femoroacetabular Cam Impingement: Accuracy and Early Clinical Outcome." Arthroscopy: The Journal of Arthroscopic and Related Surgery **24**(1): 51-57.
- Stulberg, S. D., L. D. Cordell, et al. (1975). Unrecognized childhood hip disease: a major cause of idiopathic osteoarthritis of the hip. Proceedings of the third open scientific meeting of the hip society, St. Louis.
- Tannast, M., D. Goricki, et al. (2008). "Hip Damage Occurs at the Zone of Femoroacetabular Impingement." Clinical Orthopaedics and Related Research **466**: 273-280.
- Tanzer, M. and N. Noiseux (2004). "Osseous Abnormalities and Early Osteoarthritis." Clinical Orthopaedics and Related Research **429**: 170-177.
- Vogt, L., W. Banzer, et al. (2004). "Muscle Activation Pattern of Hip Arthroplasty Patients in Walking." Research in Sports Medicine **12**: 191-199.
- Weiland, D. E. and M. J. Philippon (2005). "Arthroscopic Technique of Femoroacetabular Impingement." Operative Techniques in Orthopaedics **15**: 256-260.
- Winter, D. A. (1983). "Biomechanical motor patterns in normal walking." Journal of Motor Behavior **15**(4): 302-330.
- Winter, D. A. (2005). Biomechanics and Motor Control of Human Movement. New Jersey, USA, John Wiley & Sons Inc.
- Wisniewski, S. J. and B. Grogg (2006). "Femoroacetabular Impingement. An overlooked Cause of Hip Pain." American Journal of Physical Medicine & Rehabilitation **85**(6): 546-549.
- Woltring, H. J. (1986). "A Fortran package for generalized, cross-validatorspline smoothing and differentiation." Advances in Engineering Software **8**(2): 104-113.

SECOND ARTICLE

*Preoperative and Postoperative Lower-Extremity Joint
and Pelvic Kinematics During Maximal Squatting of
Patients with Cam Femoroacetabular Impingement*

Mario Lamontagne^{ab}, Nicholas Brisson^a, Matthew J. Kennedy^a and Paul E. Beaulé^c

^a School of Human Kinetics, University of Ottawa, Canada

^b Department of Mechanical Engineering, University of Ottawa, Canada

^c Division of Orthopaedic Surgery, The Ottawa Hospital, Canada

Introduction

Cam femoroacetabular impingement (FAI), an idiopathic progressive pathological condition of the hip in young and active adults (Wisniewski and Grogg 2006; Beaulé, LeDuff et al. 2007), has been reported to affect 17% of all males and 4% of all females (Gosvig, Jacobsen et al. 2008). This abnormality results from an asphericity of the femoral head-neck junction, causing a localized increase in its radius (Ganz, Parvizi et al. 2003). Usually at the limits of hip motion (Ganz, Parvizi et al. 2003), the aspherical femoral head is forced into the acetabulum, causing impingement and pain (Ito, Minka-II et al. 2001; Nötzli, Wyss et al. 2002; Beck, Leunig et al. 2004a; Beck, Kalhor et al. 2005; Leunig, Beck et al. 2005). Over time, this may lead to a labral tear or detachment and damage to articular cartilage (Eijer, Myers et al. 2001; Ganz, Parvizi et al. 2003; Lavigne, Parvizi et al. 2004; Tanzer and Noiseux 2004; Beck, Kalhor et al. 2005; Leunig, Beck et al. 2005; Philippon and Schenker 2006; Tannast, Goricki et al. 2008), defects thought to be an underlying cause of hip osteoarthritis (Murray 1965; Stulberg, Cordell et al. 1975; Harris 1986; Ito, Minka-II et al. 2001; Ganz, Parvizi et al. 2003; Beck, Leunig et al. 2004b; Leunig, Beck et al. 2005).

The symptoms and progression of cam FAI may be attenuated by conservative treatment, but surgical intervention is often necessary (Lavigne, Parvizi et al. 2004; Leunig, Beck et al. 2005; Guanche and Bare 2006). Several surgical procedures (Ganz, Gill et al. 2001; Clohisy and McClure 2005; Philippon and Schenker 2006) indicated for young patients without severe damage to articular surfaces (Beck, Leunig et al. 2004b; Leunig, Beck et al. 2005; Sampson 2005; Mardones, Gonzalez et al. 2006) have been developed to correct cam FAI by removing the osseous abnormality from the femoral head-neck junction

in hopes of reducing hip pain and restoring normal hip function (Ganz, Gill et al. 2001; Lavigne, Parvizi et al. 2004; Leunig, Beck et al. 2005).

Many studies have qualitatively measured the outcome of cam FAI corrective surgery using validated disease-specific questionnaires such as the Harris Hip Score (Harris 1969) and the Western Ontario and McMaster Universities Osteoarthritis Index (WOMAC) (Bellamy, Buchanan et al. 1988) to assess hip pain and functionality (Peters and Erickson 2006; Beaulé, LeDuff et al. 2007; Ilizaliturri Jr, Orozco-Rodriguez et al. 2008; Byrd and Jones 2009; Lincoln, Johnston et al. 2009). Other studies have quantitatively compared the passive ROM of the hip in patients with cam FAI before and after corrective surgery (Stähelin, Stähelin et al. 2008; Lincoln, Johnston et al. 2009). However, to our knowledge, no study has used motion analysis to compare quantitatively the preoperative and postoperative lower-extremity joint biomechanics of patients with cam FAI during activities of daily living. Understanding how the lower-extremity joints function during everyday movements following cam FAI corrective surgery is essential in determining the effect of surgery on restoring the normal biomechanics of the hip.

Deep squatting or maximal depth squatting is a controlled movement that requires a great amount of hip and pelvis motion, approaching the extremes of hip motion in individuals with cam FAI (Flanagan, Salem et al. 2003; Kubiak-Langer, Tannast et al. 2007; Philippon, Maxwell et al. 2007). Although not a common daily activity on its own, squatting is a constituent of various activities performed on a daily basis by most individuals. This movement was selected to serve as an appropriate test to evaluate lower-extremity joint function in patients having undergone cam impingement surgery.

The normal lower-extremity joint and pelvic kinematics during unloaded squatting have been well characterized in a variety of populations (Flanagan, Salem et al. 2003;

Hemmerich, Brown et al. 2006; Manabe, Shimada et al. 2007; Hwang, Kim et al. 2009). However, the only study that has examined joint kinematics during squatting in preoperative patients with cam FAI was completed in our laboratory (Lamontagne, Kennedy et al. 2009). In that study, we compared patients with cam FAI before surgery and healthy control subjects with respect to hip and pelvic angles during maximal depth squatting and noted differences in the sagittal pelvic ROM and squat depth between the two groups. To our knowledge, no study has compared the preoperative and postoperative lower-extremity joint kinematics of patients with cam FAI during maximal depth squatting.

The purpose of the present study was to compare lower-extremity joint and pelvic angular displacements during maximal depth squatting of patients with unilateral symptomatic cam FAI before and after corrective surgery. Our hypotheses were that maximal squat depth would improve after surgery (allowing greater descent of the hip joints as a percentage of leg length) and that the range of sagittal plane pelvic motion over the squat cycle would be greater postoperatively. These hypotheses were founded on the assumption that preoperative differences in maximal squat depth and sagittal plane pelvic mobility in patients with cam FAI would shift toward the results of the control subjects after corrective surgery (Lamontagne, Kennedy et al. 2009).

Materials and Methods

Participants

In the first phase of the study, fifteen participants with unilateral symptomatic cam FAI were compared to eleven control subjects (Lamontagne, Kennedy et al. 2009). In the current phase of the study, seven of the fifteen cam FAI participants returned for postoperative testing. Three additional participants, part of the same cohort and among those

whose preoperative kinematic values were collected but not included in the previous report, were included in postoperative testing. Therefore, ten participants were compared preoperatively and postoperatively (Table 5). Participants were between eighteen and fifty years of age and had a positive impingement test and a visible cam deformity on anteroposterior and Dunn view radiographs (Meyer, Beck et al. 2006; Clohisy, Carlisle et al. 2008). Each participant also had an alpha angle greater than 50 degrees, which is a diagnostic feature of cam FAI (Nötzli, Wyss et al. 2002). Participants were excluded if they had hip osteoarthritis identified by substantial joint-space narrowing on radiographs of the hip, a symptomatic contralateral hip, or if the cam FAI morphology was not purely of a cam type (Lamontagne, Kennedy et al. 2009). All participants underwent corrective surgery for cam FAI, performed by the same surgeon using an open or combined technique involving the dislocation of the hip and debridement of the femoral head-neck junction (Ganz, Gill et al. 2001; Clohisy and McClure 2005; Philippon and Schenker 2006). Postoperative testing of each participant occurred between eight and thirty-two months following surgical intervention. The study was approved by the hospital and the university research ethics boards, and informed written consent was obtained from each participant.

Table 5. Preoperative (PRE) and postoperative (POST) descriptive characteristics of participants with cam FAI. Values are expressed as mean \pm standard deviation.

Group	Male/Female (n)	Age (years)	BMI (kg/m ²)	WOMAC (%)	Flexibility (cm)
PRE	7/3	29.9 \pm 7.2	23.3 \pm 2.7	78.1 \pm 14.3	21.8 \pm 8.8
POST	7/3	32.3 \pm 7.2	24.8 \pm 3.1	82.2 \pm 14.8	24.5 \pm 8.6

Instrumentation

Three-dimensional (3-D) lower-extremity joint and pelvic kinematics of the participants, as they performed maximal depth squats, were collected using nine VICON

MX-13 cameras (VICON, Los Angeles, California) at 200 Hz with forty-five reflective markers placed on anatomical landmarks according to a modified Helen-Hayes marker-set (Lamontagne, Kennedy et al. 2009). A height-adjustable bench, set to one-third of the tibial plateau height, was used as a maximal depth indicator and served as a means of injury prevention if participants lost their balance and fell backwards during a trial.

Experimental Protocol

The same experimental protocol was used for preoperative and postoperative testing (Lamontagne, Kennedy et al. 2009). The participants performed a static calibration trial, in which they stood in a neutral position with their feet shoulder-width apart and facing anteriorly, their legs straight, and their arms at their sides. These static trials were used to calculate each participant's segment lengths and determine their neutral joint angles. Then, participants performed five maximal depth squat trials. Maximal depth corresponded to the height of the adjusted bench or, if they were unable to attain this depth, the lowest attainable depth. To perform this manoeuvre, participants stood in an upright position, approximately 10 cm in front of the bench and positioned their feet shoulder-width apart, parallel to each other and facing anteriorly. With their arms extended anteriorly (Isear, Erickson et al. 1997) to improve balance and prevent their use for support (Schultz, Alexander et al. 1992; Janssen, Bussmann et al. 2002), participants squatted at a self-selected and controlled pace (Pai and Rogers 1991) until their buttocks slightly touched the bench – not applying a significant amount of weight onto the bench – and then ascended back to a standing position. If participants could not squat to the bench depth, they squatted to their lowest attainable depth. Participants were required to keep their feet flat on the ground and maintain their centre of mass between their feet in order for a trial to be deemed successful.

Data Processing and Analysis

Three-dimensional lower-extremity joint kinematics were calculated according to the methods previously described by Kadaba et al. (Kadaba, Ramakrishnan et al. 1989; Kadaba, Ramakrishnan et al. 1990) and Davis et al. (DavisIII, Ounpuu et al. 1991). The hip, knee and ankle joints were assigned three rotational degrees of freedom (i.e., flexion-extension, abduction-adduction, internal-external rotation). The rotations at each of these joints were expressed as the orientation of the proximal segment (e.g., pelvis) in relation to the distal segment (e.g., thigh) and were defined by an Euler angle convention (YXZ). Similarly, the pelvis was assigned three rotational degrees of freedom (i.e., pitch, obliquity and rotation, which were measured in the sagittal, frontal and transverse planes, respectively) relative to a global coordinate system. Joint angles were expressed in relation to each participant's neutral position as determined by a standing static trial.

Squat kinematic variables consisted of the hip, knee and ankle angles in each plane, and the sum of all joint angles of the affected limb in the sagittal plane at maximal squat depth, the maximal pelvic angle in each plane, the pelvic angular value at maximal squat depth, the overall pelvic motion in each plane, and the maximal squat depth attained. Lower-extremity joint angles were assessed only at maximal squat depth since that tended to be the only instance when maximum joint angles were observed in the sagittal plane. Maximal squat depth (percent of leg length) was defined as the lowest point attained by the hip joint centers (distance from the floor) during the squat, divided by the participant's leg length, which corresponded to the averaged linear distance between the medial malleoli and their respective anterior superior iliac spine. A lower percentage value corresponded to a greater squat depth. For each participant, the kinematic variables of interest were obtained for all five individual squat trials, and then were averaged.

Statistical Analysis

Multiple repeated-measures multivariate analyses of variance (MANOVAs) were conducted to determine the presence of significant differences between the preoperative and postoperative measurements of cam FAI patients, with regard to the 3-D hip, knee, ankle and pelvic angles during maximal depth squatting. The alpha value was set at 0.05 for all statistical analyses regarding the lower-extremity joint angles. For all statistical analyses concerning pelvic angular displacements, a Bonferroni correction was used to adjust the alpha value to 0.017 ($p < 0.05/3$) because three comparisons were made in each plane (maximum value, value at peak squat depth and the pelvic ROM) (Feise 2002). All statistical tests were conducted using SPSS software version 15.0 (SPSS Inc., Chicago, Illinois).

Results

Results from the repeated-measures MANOVAs revealed no significant difference between the preoperative and postoperative measurements of the cam FAI patients with respect to the kinematics of the affected hip at maximal squat depth, the pelvic angular displacements at maximal squat depth, or the overall pelvic motion ($p > 0.05$) during maximal depth squatting. While preoperative and postoperative squatting speeds were similar, maximal squat depths were significantly different. Postoperatively, participants squatted to a greater mean maximal depth (and standard deviation) of $33.2\% \pm 10.3\%$ of leg length compared to $36.9\% \pm 12.0\%$ preoperatively ($p = 0.027$) (Table 6). The mean postoperative knee flexion angles of the affected limb ($141.5^\circ \pm 19.2^\circ$) at maximal squat depth were significantly greater ($p = 0.005$) than preoperative values ($130.6^\circ \pm 19.4^\circ$). Similarly, the postoperative ankle dorsiflexion angles of the affected limb at maximal squat depth were greater than the preoperative values ($p = 0.048$). Since squatting is a closed

kinematic chain movement, the maximal squat depth is attained by the angular summation of the three lower-extremity joints. The postoperative sum of all joint angles of the affected limb at maximal squat depth ($277.9^\circ \pm 35.5^\circ$) was significantly larger ($p = 0.006$) than the preoperative sum ($263.2^\circ \pm 33.1^\circ$) (Table 6). A post-hoc power analysis was conducted using G*POWER 3 (Faul, Erdfelder et al. 2007). With a sample size of ten, an alpha value set at 0.05, and maximal squat depth used as the key dependent variable, the power of the study was determined to be 65%.

Table 6. Preoperative (PRE) and postoperative (POST) hip, knee and ankle joint angles, and the sum of all joint angles in the sagittal plane of the affected limb at maximal squat depth, and the maximal squat depth as a percentage of leg length for each participant.

Participant	Hip angles (degrees)		Knee angles* (degrees)		Ankle angles* (degrees)		Sum of all joint angles* (degrees)		Squat Depths* (%)	
	PRE	POST	PRE	POST	PRE	POST	PRE	POST	PRE	POST
1	120	118	145	152	31	36	296	306	34.4	34.8
2	105	104	134	147	24	27	263	278	33.6	28.5
3	109	112	135	148	22	26	266	286	36.2	30.8
4	102	99	144	156	26	45	272	300	26.4	25.4
5	112	101	139	152	19	33	270	286	29.5	25.2
6	116	105	135	147	24	29	275	281	31.3	27.6
7	117	111	142	152	23	34	282	298	28.6	26.6
8†	93	102	94	117	22	27	209	246	60.1	45.5
9†	101	91	95	96	17	17	213	204	58.0	57.0
10	124	119	143	148	21	29	288	296	30.9	31.0
Mean	109.8	106.2	130.6	141.5	22.8	30.2	263.2	277.9	36.9	33.2
Standard deviation	9.7	8.8	19.4	19.2	4.0	7.5	33.1	35.5	12.0	10.3

* The difference between the mean preoperative and postoperative measurements was significant ($p < 0.05$). † Participants with atypical pelvic mobility.

Discussion

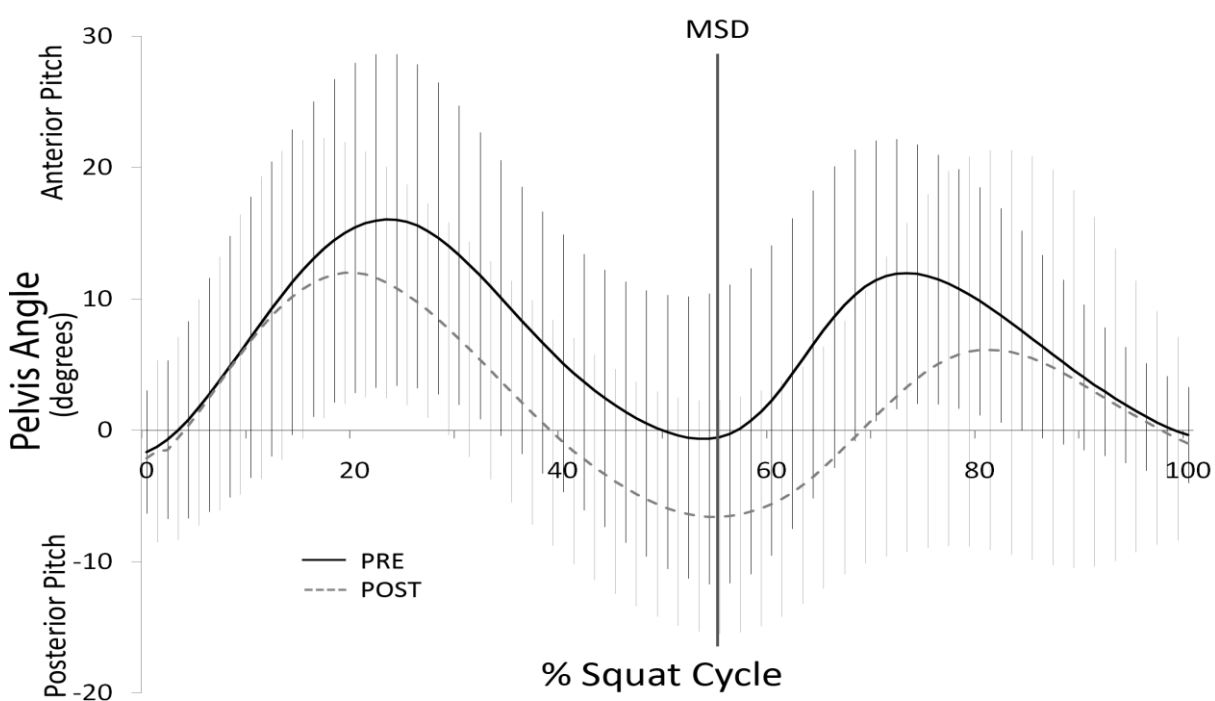
The first hypothesis of this study was confirmed as the participants attained greater postoperative squat depths as a percentage of leg length. Conversely, the second hypothesis concerning the range of sagittal plane pelvic motion over the squat cycle was rejected, as the postoperative measurements were not significantly greater.

Many investigations have assessed the outcome of cam FAI surgery subjectively and qualitatively (Peters and Erickson 2006; Beaulé, LeDuff et al. 2007; Ilizaliturri Jr, Orozco-Rodriguez et al. 2008; Byrd and Jones 2009; Lincoln, Johnston et al. 2009). To our knowledge, this is the first study that used motion analysis to compare the preoperative and postoperative pelvic and lower-extremity joint kinematics of patients with cam FAI during maximal depth squatting, ascertaining whether surgery effectively restored the lower-extremity joint biomechanics to within a normal range of values. Since maximal depth squatting necessitates substantial hip motion, it was considered a valuable test in the evaluation of lower-extremity joint function following corrective surgery for cam FAI.

In the first phase of the study, Lamontagne et al. (2009) compared the 3-D hip angles at maximal squat depth, the pelvic angular displacements during descent, ascent and at maximal depth, as well as the overall pelvic motion during maximal depth squatting for fifteen patients with cam FAI and eleven healthy control subjects (Lamontagne, Kennedy et al. 2009). The results revealed that the control group could squat lower than the FAI group by an average of 9.2% of leg length. Furthermore, the FAI group had a smaller mean sagittal plane pelvic ROM ($14.7^{\circ} \pm 8.4^{\circ}$) compared to the control group ($24.2^{\circ} \pm 6.8^{\circ}$). Conversely, no differences in the 3-D hip angles at maximal squat depth were noted between the two groups. In the current study, there were no significant differences between preoperative and postoperative pelvic ROM, as well as pelvic and hip angles at maximal squat depth. However, the overall squat performance improved postoperatively, likely from the increase in knee flexion, ankle dorsiflexion, and the summed angular displacements of all joints of the affected limb. This finding may also be partially explained by the increased pelvic posterior pitch during the descent phase of the squat (Figure 4), although this was not significant because of two participants who had atypical pelvic mobility (Table 6). This increase in

postoperative pelvic motion during squatting would likely have an effect on squat depth by increasing the distance between the anterior acetabular edge and the femoral neck (Reynolds, Lucas et al. 1999), thus reducing anterior femoral head coverage and preventing impingement (Konishi and Mieno 1993).

Figure 4. The mean pelvic pitch (in degrees) of the preoperative (PRE) and postoperative (POST) cam FAI groups during maximal depth squatting. Hash marks represent the standard deviations, and the vertical line indicates the maximal squat depth (MSD).



When the preoperative squat kinematic values were compared to the postoperative values, no differences in lower-extremity joint and pelvic motions were found with the exception of the mean knee flexion and ankle dorsiflexion angles of the affected limbs at maximal squat depth, which increased postoperatively by 10.9° and 7.4° , respectively. In addition, participants attained greater postoperative squat depths of 3.7% of leg length compared to preoperative tests.

The greater mean postoperative squat depth likely contributed to increased postoperative knee flexion and ankle dorsiflexion angles (Table 6), although it is uncertain how knee and ankle mobility would be affected by hip surgery. Interestingly, though, the greater mean squat depth observed postoperatively may also be attributable to the increased pelvic mobility, which may have been affected by the hip surgery.

It was also observed that hip motion during squatting was not significantly different between the preoperative FAI group and the control group (Lamontagne, Kennedy et al. 2009). Similarly, no significant differences were found in hip kinematics during squatting between preoperative and postoperative values, suggesting that peak hip flexion does not limit squat depth in individuals with cam FAI. The postoperative improvement in squat depth was likely achieved by the combined contribution of all lower-extremity joints, including the increased posterior pelvic pitch during the descent phase of the squat. Possibly, the corrective surgery eliminated the mechanical restriction (i.e. bone tissue) and decreased joint pain by debridement of the unstable labrum (Fitzgerald Jr 1995).

Conversely, the relatively small sample size and wide variability in postoperative test times (ranging from eight to thirty-two months) could have affected the detection of significant differences between preoperative and postoperative kinematic values.

Future research should aim to evaluate the roles played by the muscles and ligaments of cam FAI patients during movements requiring a large ROM of the lower-extremity joints and pelvis. Exposing the causes of movement restrictions can aid in perfecting surgical techniques and developing better rehabilitation programs for patients with FAI, thus improving postoperative joint function.

References

- Beaulé, P. E., M. J. LeDuff, et al. (2007). "Quality of Life Following Femoral Head-Neck Osteochondroplasty for Femoroacetabular Impingement." The Journal of Bone & Joint Surgery **89-A**: 773-779.
- Beck, M., M. Kalthor, et al. (2005). "Hip morphology influences the pattern of damage to the acetabular cartilage." The Journal of Bone & Joint Surgery **87-B**(7): 1012-1018.
- Beck, M., M. Leunig, et al. (2004a). "Femoroacetabular Impingement as a Factor in the Development of Nonunion of the Femoral Neck." Journal of Orthopaedic Trauma **18**(7): 425-430.
- Beck, M., M. Leunig, et al. (2004b). "Anterior Femoroacetabular Impingement. Part I. Techniques of Joint Preserving Surgery." Clinical Orthopaedics **418**: 67-73.
- Bellamy, N., W. W. Buchanan, et al. (1988). "Validation study of WOMAC: A health status instrument for measuring clinically important patient relevant outcomes to antirheumatic drug therapy in patients with osteoarthritis of the hip or knee." The Journal of Rheumatology **15**: 1833-1840.
- Byrd, J. W. T. and K. S. Jones (2009). "Arthroscopic Femoroplasty in the Management of Cam-type Femoroacetabular Impingement." Clinical Orthopaedics and Related Research **467**: 739-746.
- Clohisy, J. C., J. C. Carlisle, et al. (2008). "A Systematic Approach to the Plain Radiographic Evaluation of the Young Adult Hip." The Journal of Bone & Joint Surgery **90-A**: 47-66.
- Clohisy, J. C. and J. T. McClure (2005). "Treatment of anterior femoroacetabular impingement with combined hip arthroscopy and limited anterior decompression." The Iowa Orthopaedic Journal **25**: 164-171.
- DavisIII, R. B., S. Ounpuu, et al. (1991). "A gait analysis data collection and reduction technique." Human Movement Science **10**(5): 575-587.
- Eijer, H., S. R. Myers, et al. (2001). "Anterior Femoroacetabular Impingement After Femoral Neck Fractures." Journal of Orthopaedic Trauma **15**(7): 475-481.
- Faul, F., E. Erdfelder, et al. (2007). "G*Power 3: A flexible statistical power analysis program for the social, behavioral, and biomedical sciences." Behavior Research Methods **39**(2): 175-191.
- Flanagan, S., G. J. Salem, et al. (2003). "Squatting Exercises in Older Adults: Kinematic and Kinetic Comparisons." Medicine & Science in Sports & Exercise **35**(4): 635-643.
- Ganz, R., T. J. Gill, et al. (2001). "Surgical dislocation of the adult hip." The Journal of Bone & Joint Surgery **83-B**(8): 1119-1124.
- Ganz, R., J. Parvizi, et al. (2003). "Femoroacetabular Impingement. A Cause for Osteoarthritis of the Hip." Clinical Orthopaedics and Related Research **417**: 112-120.
- Guanche, C. A. and A. A. Bare (2006). "Arthroscopic Treatment of Femoroacetabular Impingement." Arthroscopy: The Journal of Arthroscopic and Related Surgery **22**(1): 95-106.
- Harris, W. H. (1969). "Traumatic arthritis of the hip after dislocation and acetabular fractures: treatment by mold arthroplasty. An end-result study using a new method of result evaluation." The Journal of Bone and Joint Surgery **51-A**(4): 737-755.
- Harris, W. H. (1986). "Etiology of Osteoarthritis of the Hip." Clinical Orthopaedics and Related Research **213**: 20-33.

- Hemmerich, A., H. Brown, et al. (2006). "Hip, Knee, and Ankle Kinematics of High Range of Motion Activities of Daily Living." Journal of Orthopaedic Research **24**: 770-781.
- Hwang, S., Y. Kim, et al. (2009). "Lower extremity joint kinetics and lumbar curvature during squat and stoop lifting." BMC Musculoskeletal Disorders **10**(15).
- Ilizaliturri Jr, V. M., L. Orozco-Rodriguez, et al. (2008). "Arthroscopic Treatment of Cam-Type Femoroacetabular Impingement." The Journal of Arthroplasty **23**(2): 226-234.
- Isear, J., J. Erickson, et al. (1997). "EMG analysis of lower extremity muscle recruitment patterns during an unloaded squat." Medicine & Science in Sports & Exercise **29**(4): 532-539.
- Ito, K., M.-A. Minka-II, et al. (2001). "Femoroacetabular impingement and the cam-effect. A MRI-based quantitative anatomical study of the femoral head-neck offset." The Journal of Bone & Joint Surgery **83-B**(2): 171-176.
- Janssen, W., H. Bussmann, et al. (2002). "Determinants of the Sit-to-Stand Movement: A Review." Physical Therapy **82**(9): 866-875.
- Kadaba, M. P., H. K. Ramakrishnan, et al. (1990). "Measurement of Lower Extremity Kinematics During Level Walking." Journal of Orthopaedic Research **8**: 383-392.
- Kadaba, M. P., H. K. Ramakrishnan, et al. (1989). "Repeatability of Kinematic, Kinetic, and Electromyographic Data in Normal Adult Gait." Journal of Orthopaedic Research **7**: 849-860.
- Konishi, N. and T. Mieno (1993). "Determination of acetabular coverage of the femoral head with use of a single anteroposterior radiograph. A new computerized technique." The Journal of Bone & Joint Surgery (Am) **75**(9): 1318-1333.
- Kubiak-Langer, M., M. Tannast, et al. (2007). "Range of Motion in Anterior Femoroacetabular Impingement." Clinical Orthopaedics and Related Research **458**: 117-124.
- Lamontagne, M., M. J. Kennedy, et al. (2009). "The Effect of Cam FAI on Hip and Pelvic Motion during Maximum Squat." Clinical Orthopaedics and Related Research **467**: 645-650.
- Laude, F., T. Boyer, et al. (2007). "Anterior femoroacetabular impingement." Joint Bone Spine **74**: 127-132.
- Lavigne, M., J. Parvizi, et al. (2004). "Anterior Femoroacetabular Impingement. Part II. Midterm Results of Surgical Treatment." Clinical Orthopaedics **418**: 61-66.
- Leunig, M., M. Beck, et al. (2005). "Femoroacetabular Impingement: Etiology and Surgical Concept." Operative Techniques in Orthopaedics **15**: 247-255.
- Lincoln, M., K. Johnston, et al. (2009). "Combined Arthroscopic and Modified Open Approach for Cam Femoroacetabular Impingement: A Preliminary Experience." Arthroscopy: The Journal of Arthroscopic and Related Surgery **25**(4): 392-399.
- Manabe, Y., K. Shimada, et al. (2007). "Effect of slow movement and stretch-shortening cycle on lower extremity muscle activity and joint moments during squat." Journal of Sports Medicine and Physical Fitness **47**: 1-12.
- Mardones, R. M., C. Gonzalez, et al. (2006). "Surgical Treatment of Femoroacetabular Impingement: Evaluation of the Effect of the Size of the Resection." The Journal of Bone & Joint Surgery **88-A**: 84-91.
- Meyer, D. C., M. Beck, et al. (2006). "Comparison of Six Radiographic Projections to Assess Femoral Head/Neck Asphericity." Clinical Orthopaedics and Related Research **445**: 181-185.

- Murray, R. O. (1965). "The aetiology of primary osteoarthritis of the hip." The British Journal of Radiology **38**: 810-824.
- Nötzli, H. P., T. F. Wyss, et al. (2002). "The contour of the femoral head-neck junction as a predictor for the risk of anterior impingement." The Journal of Bone & Joint Surgery **84-B**: 556-560.
- Pai, Y. C. and M. W. Rogers (1991). "Speed variation and resultant joint torques during sit-to-stand." Archives of Physical Medicine and Rehabilitation **72**(11): 881-885.
- Peters, C. L. and J. A. Erickson (2006). "Treatment of Femoro-Acetabular Impingement with Surgical Dislocation and Débridement in Young Adults." The Journal of Bone & Joint Surgery **88-A**(8): 1735-1741.
- Philippon, M. J., R. B. Maxwell, et al. (2007). "Clinical presentation of femoroacetabular impingement." Knee Surgery, Sports Traumatology, Arthroscopy **15**: 1041-1047.
- Philippon, M. J. and M. L. Schenker (2006). "Arthroscopy for the Treatment of Femoroacetabular Impingement in the Athlete." Clinical Sports Medicine **25**: 299-308.
- Philippon, M. J. and M. L. Schenker (2006). "A New Method for Acetabular Rim Trimming and Labral Repair." Clinical Sports Medicine **25**: 293-297.
- Reynolds, D., J. Lucas, et al. (1999). "Retroversion of the acetabulum. A Cause of Hip Pain." The Journal of Bone & Joint Surgery (Br) **81-B**(2): 281-288.
- Sampson, T. G. (2005). "Arthroscopic Treatment of Femoroacetabular Impingement." Techniques in Orthopaedics **20**(1): 56-62.
- Schultz, A. B., N. B. Alexander, et al. (1992). "Biomechanical analyses of rising from a chair." Journal of Biomechanics **25**(12): 1383-1391.
- Stähelin, L., T. Stähelin, et al. (2008). "Arthroscopic Offset Restoration in Femoroacetabular Cam Impingement: Accuracy and Early Clinical Outcome." Arthroscopy: The Journal of Arthroscopic and Related Surgery **24**(1): 51-57.
- Stulberg, S. D., L. D. Cordell, et al. (1975). Unrecognized childhood hip disease: a major cause of idiopathic osteoarthritis of the hip. Proceedings of the third open scientific meeting of the hip society, St. Louis.
- Tannast, M., D. Goricki, et al. (2008). "Hip Damage Occurs at the Zone of Femoroacetabular Impingement." Clinical Orthopaedics and Related Research **466**: 273-280.
- Tanzer, M. and N. Noiseux (2004). "Osseous Abnormalities and Early Osteoarthritis." Clinical Orthopaedics and Related Research **429**: 170-177.
- Wisniewski, S. J. and B. Grogg (2006). "Femoroacetabular Impingement. An overlooked Cause of Hip Pain." American Journal of Physical Medicine & Rehabilitation **85**(6): 546-549.

DISCUSSION & CONCLUSION

Cam FAI is primarily the result of a mechanical restriction of the hip, which can lead to labral and chondral damage, and progress into hip osteoarthritis (Ganz, Parvizi et al. 2003; Leunig, Beck et al. 2005). Corrective surgery for cam FAI can be performed using various techniques, all of which aim to alleviate hip pain by restoring a normal femoral head-neck offset (Ganz, Gill et al. 2001; Clohisy and McClure 2005; Philippon and Schenker 2006). Several studies have used questionnaires to assess qualitatively the outcome of corrective surgery for cam FAI, demonstrating reductions in hip pain and restoration of hip function, postoperatively (Peters and Erickson 2006; Beaulé, LeDuff et al. 2007; Lincoln, Johnston et al. 2009). Likewise, postoperative improvements in hip passive ROM have been reported (Lincoln, Johnston et al. 2009). Despite this, to our knowledge, no study has quantified the outcome of cam FAI surgery using motion analysis and ground reaction forces; valuable methods in the evaluation of lower-extremity joint function. Assessing postoperative hip function of cam FAI patients during activities of daily living is crucial in ensuring that surgery effectively restores more normal biomechanics of the lower-extremity joints.

The purpose of this study was to determine the effects of cam FAI corrective surgery on the pelvic and lower-extremity joint mechanics of FAI patients during level walking and maximal depth squatting. We hypothesized that, for both tasks, the pelvic and lower-extremity joint mechanics of FAI patients following corrective surgery would improve and resemble more those of the healthy control participants.

The results from the present study did not support our hypothesis with respect to level walking, as the affected lower-extremity joint biomechanics of cam FAI patients did not return to normal following corrective surgery. On the other hand, our hypothesis was

somewhat verified regarding maximal depth squatting as cam FAI patients attained greater squat depths postoperatively, suggesting improvements in pelvic and lower-extremity joint mobility even though pelvic pitch did not statistically significantly improve. It can be inferred that, although the open and combined surgical techniques were efficient in restoring a normal femoral head-neck offset, eradicating hip impingement, and reducing hip and groin pain in individuals with cam FAI, they may not yet be perfected as to allow complete restoration of normal hip function. The subsequent sections summarize the main findings of this study and address its limitations.

During level walking, both the preoperative and postoperative FAI groups had significantly lower hip frontal plane ROM compared to the control group. In addition, the postoperative FAI group had a significantly reduced hip sagittal plane ROM, as well as reduced peak hip abduction and external rotation moments, and peak hip power generation compared to the control group (Table 4, page 36).

Because the hip solicits only a fraction of its maximal dynamic ROM in the frontal and sagittal planes during gait (Kennedy, Lamontagne et al. 2009a; Kennedy, Lamontagne et al. 2009b), it is reasonable to assume that the reductions in hip kinematics observed in FAI patients were not the result of a mechanical restriction caused by an aspherical femoral head. Instead, it is believed that hip motion was altered as a result of joint stabilization strategies adopted by FAI patients to counteract hip muscular deficiencies. Specifically, it was thought that at the time of transfer from double-limb stance to single-limb stance onto the affected limb, like other hip surgery patients, FAI patients adopted a pelvic stabilization technique, which reduced their hip motion in the frontal plane, allowing them to produce smaller hip abduction and external rotation moments to counteract opposing moments produced by their centre of mass (Beaulieu, Lamontagne et al. 2010).

It is speculated that the lower than normal lower-extremity joint kinetic measurements observed in preoperative FAI patients resulted from muscle disuse and atrophy caused by modified gait patterns that they adopted to reduce hip muscle contractions, loading and pain (Beaulieu, Lamontagne et al. 2010). On the other hand, further reductions in postoperative hip abduction and external rotation moments may have been caused by the surgery. Similar results have been observed in patients who underwent total hip arthroplasty – surgery which requires muscle incisions similar to those seen in the open and combined techniques used in the treatment of cam FAI – and have been proposed to result from weakened hip abductors, postoperatively (Vogt, Banzer et al. 2004; Foucher, Hurwitz et al. 2007). Particularly, major contributors to hip motion such as the gluteus maximus, tensor fascia latae and rectus femoris muscles were incised during cam FAI corrective surgery, and a lack of their complete recovery may explain the postoperative biomechanical reductions observed at the hip in all three planes of motion. However, due to a lack of preoperative and postoperative electromyography data of the lower-extremity muscles of cam FAI patients, it is impossible to confirm this speculation.

Concerning maximal depth squat, postoperatively, FAI patients squatted to a greater mean maximal depth as a percentage of leg length compared to preoperatively. The mean postoperative knee flexion and ankle dorsiflexion angles, as well as the sum of all joint angles of the affected limb at maximal squat depth were significantly greater than the preoperative values (Table 6, page 54). Conversely, no significant differences were detected between the preoperative and postoperative hip kinetics, and pelvic and hip kinematics.

The overall squat performance improved postoperatively, likely from the increase in knee flexion and ankle dorsiflexion angles, and the summed angular displacements of all joints of the affected limb. Similarly, the greater squat depths attained postoperatively were

probably the primary cause of increased knee flexion and ankle dorsiflexion angles. The improved squat performance may also be partially explained by the increased pelvic posterior pitch during the descent phase of the squat (Figure 4, page 56), although this was not statistically significant because of two participants who had atypical pelvic mobility (Table 6, page 54). This increase in postoperative pelvic motion during squatting would likely have an effect on squat depth by increasing the distance between the anterior acetabular edge and the femoral neck (Reynolds, Lucas et al. 1999), thereby reducing anterior femoral head coverage and preventing impingement (Konishi and Mieno 1993). It is also possible that the surgery eliminated the mechanical restriction and reduced joint pain by debridement of the unstable labrum (Fitzgerald Jr 1995), allowing FAI patients to better perform the squat manoeuvre.

The present study had several noteworthy limitations. Firstly, two surgical techniques were used to correct the cam deformity in FAI patients. The open and combined surgical techniques affected different soft tissues of the hip. Despite this, all FAI patients were combined into one postoperative group, making it impossible to discern the effects of each surgery on hip outcome measurements. Secondly, the lack of preoperative and postoperative electromyography data of the lower-extremity muscles of cam FAI patients made it difficult to determine the exact causes of the reductions observed in hip joint mechanics during level walking. Thirdly, the use of preoperative and postoperative pain medication was not controlled in this study. This may have affected the pain scores observed by the WOMAC index; the postoperative improvements may have been lesser or greater. Likewise, a reduction in pain due to medication could have allowed the FAI participants to better perform the squat manoeuvre (i.e. squat deeper as a result of reduced or absence of pain), affecting the results. Fourthly, the effects of rehabilitation on the FAI patients, both

preoperatively and postoperatively, were not controlled. To aid in their recovery, all patients followed a rehabilitation program consisting of exercises aiming to strengthen hip muscles and restore hip ROM. The specific protocols and level of compliance, however, were not noted. Physiotherapy could have altered the outcome measurements since it has been demonstrated that patients who are more committed to their rehabilitation program return to higher levels of functionality (Marker, Seyler et al. 2010).

The current study was also subject to limitations which are intrinsic to joint kinematic studies. Of note, inaccurate retro-reflective marker placement (Della Croce, Leardini et al. 2005) as well as skin and clothing artefacts (Reinschmidt, van den Bogert et al. 1997; Leardini, Chiari et al. 2005; Benoit, Ramsey et al. 2006) can affect the determination of joint centres and thus skew research outcomes. Specifically, inter-examiner variability may have altered the lower-extremity joint kinematics measured between the two phases of the study seeing as the marker placements were performed by two investigators (MK in the first phase and NB in the second phase) (Della Croce, Leardini et al. 2005). The impact of this source of variability was reduced, however, because the same marker-set was utilized for both preoperative and postoperative tests, and multiple pilot tests were performed during which the investigators discussed the proper method of identifying anatomical landmarks and marker placement sites, assuring consistency throughout the first and second phases of the study. Similarly, intra-examiner variability has been shown to range from 0.5-2 centimetres with respect to lower-extremity marker placement (Della Croce, Leardini et al. 2005). The effect of these potential errors, however, was greatly reduced given that all joint angles were zeroed based on each participant's neutral static trial during each testing period. Moreover, the location of each joint centre is estimated with use of retro-reflective markers affixed to the participant's skin and clothing, which can move independently of the underlying bone,

creating artefact. To counter the effects of clothing artefact, participants wore form-fitting clothing. Although walking was performed at a natural speed, squatting was performed in a slow and controlled fashion, reducing the effects of skin artefact (Leardini, Chiari et al. 2005). Another limitation is that anthropometric data obtained from cadaveric studies (Dempster 1955), such as segment masses and centres of mass, were used to estimate the hip centres of rotation; generalizations that do not necessarily reflect the genuine anatomy of the participants.

In conclusion, despite the fact that this study had some limitations, it did provide valid and reliable 3-D kinematic and kinetic data on the lower-extremity joints of cam FAI patients who underwent surgery for cam FAI with use of an open or combined technique. The assessment of different tasks allowed a better understanding of the effects of cam FAI corrective surgery as postoperative improvements were seen during maximal depth squatting, while further impairments were observed during level walking. The improvements in pelvic and lower-extremity joint angular displacements observed postoperatively during maximal depth squatting advocated the benefit of having reduced pain and increased clearance for the femoral head to move within the acetabulum during movements requiring a large ROM of the hip and pelvis. The results from the level walking condition suggested that postoperatively, FAI patients exhibited reduced function of the lower-extremity joints during natural open kinematic chain movements. Specifically, the hip kinetics, and thus hip kinematics, were thought to have worsened as of result of muscle incisions during the surgery. There were great similarities between the results of the present study and those of investigations on gait of total hip arthroplasty patients, underlining the need to further investigate the link between the current surgical outcomes and the effects of muscle incisions. Although cam FAI is considered to be caused mainly by an osseous deformation of

the femoral head-neck junction, it seems that this hip pathology is associated with aberrant joint functions (i.e. muscle activation patterns, ligament tension and bone-on-bone contact) that have not yet been well identified. Further research, especially with use of electromyography, is necessary to determine the reasons for which the lower-extremity joint biomechanics of FAI patients do not completely return to normal after surgery. Exposing these causes could help to perfect surgical techniques and develop better rehabilitation programs for FAI patients.

REFERENCES

- Amstutz, H. C., B. J. Thomas, et al. (1984). "Treatment of primary osteoarthritis of the hip. A comparison of total joint and surface replacement arthroplasty." The Journal of Bone and Joint Surgery **66-A**(2): 228-241.
- Barton, C., K. Banga, et al. (2009). "Anterior Hueter Approach in the Treatment of Femoro-Acetabular Impingement: Rationale and Technique." Orthopedic Clinics of North America **40**: 389-395.
- Beaulé, P. E., M. J. LeDuff, et al. (2007). "Quality of Life Following Femoral Head-Neck Osteochondroplasty for Femoroacetabular Impingement." The Journal of Bone & Joint Surgery **89-A**: 773-779.
- Beaulieu, M. L., M. Lamontagne, et al. (2010). "Lower limb biomechanics during gait do not return to normal following total hip arthroplasty." Gait & Posture **32**: 269-273.
- Beck, M., M. Kalhor, et al. (2005). "Hip morphology influences the pattern of damage to the acetabular cartilage." The Journal of Bone & Joint Surgery **87-B**(7): 1012-1018.
- Beck, M., M. Leunig, et al. (2004a). "Femoroacetabular Impingement as a Factor in the Development of Nonunion of the Femoral Neck." Journal of Orthopaedic Trauma **18**(7): 425-430.
- Beck, M., M. Leunig, et al. (2004b). "Anterior Femoroacetabular Impingement. Part II. Midterm Results of Surgical Treatment." Clinical Orthopaedics **418**: 67-73.
- Bejek, Z., R. Paroczai, et al. (2006). "The influence of walking speed on gait parameters in healthy people and in patients with osteoarthritis." Knee Surgery, Sports Traumatology, Arthroscopy **14**: 612-622.
- Bellamy, N., W. W. Buchanan, et al. (1988). "Validation study of WOMAC: A health status instrument for measuring clinically important patient relevant outcomes to antirheumatic drug therapy in patients with osteoarthritis of the hip or knee." The Journal of Rheumatology **15**: 1833-1840.
- Benoit, D. L., D. K. Ramsey, et al. (2006). "Effect of skin movement artifact on knee kinematics during gait and cutting motions measured in vivo." Gait & Posture **24**: 152-164.
- Bhave, A., D. R. Marker, et al. (2007). "Functional Problems and Treatment Solutions After Total Hip Arthroplasty." The Journal of Arthroplasty **22**(6): 116-124.
- Byrd, J. W. T. and K. S. Jones (2009). "Arthroscopic Femoroplasty in the Management of Cam-type Femoroacetabular Impingement." Clinical Orthopaedics and Related Research **467**: 739-746.
- Christensen, C. P., P. L. Althausen, et al. (2003). "The Nonarthritic Hip Score: Reliable and Validated." Clinical Orthopaedics and Related Research **406**: 75-83.
- Clohisy, J. C., J. C. Carlisle, et al. (2008). "A Systematic Approach to the Plain Radiographic Evaluation of the Young Adult Hip." The Journal of Bone & Joint Surgery **90-A**: 47-66.
- Clohisy, J. C. and J. T. McClure (2005). "Treatment of anterior femoroacetabular impingement with combined hip arthroscopy and limited anterior decompression." The Iowa Orthopaedic Journal **25**: 164-171.
- Clohisy, J. C., R. M. Nunley, et al. (2007). "The Frog-leg Lateral Radiograph Accurately Visualized Hip Cam Impingement Abnormalities." Clinical Orthopaedics and Related Research **462**: 115-121.

- Crowinshield, R. D., R. A. Brand, et al. (1978). "The Effects of Walking Velocity and Age on Hip Kinematics and Kinetics." Clinical Orthopaedics and Related Research **132**: 140-144.
- d'Aubigné, R. M. and M. Postel (1954). "Functional Results of Hip Arthroplasty with Acrylic Prosthesis." The Journal of Bone and Joint Surgery **35-A**(451-475).
- DavisIII, R. B., S. Ounpuu, et al. (1991). "A gait analysis data collection and reduction technique." Human Movement Science **10**(5): 575-587.
- Della Croce, U., A. Leardini, et al. (2005). "Human movement analysis using stereophotogrammetry. Part 4: assessment of anatomical landmark misplacement and its effects on joint kinematics." Gait & Posture **21**: 226-237.
- Dempster, W. T. (1955). "The anthropometry of body action." Annals of the New York Academy of Sciences **63**(4): 559-585.
- Eijer, H., S. R. Myers, et al. (2001). "Anterior Femoroacetabular Impingement After Femoral Neck Fractures." Journal of Orthopaedic Trauma **15**(7): 475-481.
- Eng, J. J. and D. A. Winter (1995). "Kinetic analysis of the lower limbs during walking: what information can be gained from a three-dimensional model?" Journal of Biomechanics **28**(6): 753-758.
- Enseki, K. R., R. Martin, et al. (2010). "Rehabilitation After Arthroscopic Decompression for Femoroacetabular Impingement." Clinical Journal of Sport Medicine **29**(2): 247-255.
- Faul, F., E. Erdfelder, et al. (2007). "G*Power 3: A flexible statistical power analysis program for the social, behavioral, and biomedical sciences." Behavior Research Methods **39**(2): 175-191.
- Feise, R. J. (2002). "Do multiple outcome measures require p-value adjustment?" BMC Medical Research Methodology **2**(8).
- FitzgeraldJr, R. H. (1995). "Acetabular Labrum Tears. Diagnosis and Treatment." Clinical Orthopaedics and Related Research **311**: 60-68.
- Flanagan, S., G. J. Salem, et al. (2003). "Squatting Exercises in Older Adults: Kinematic and Kinetic Comparisons." Medicine & Science in Sports & Exercise **35**(4): 635-643.
- Foucher, K., D. Hurwitz, et al. (2007). "Preoperative gait adaptations persist one year after surgery in clinically well-functioning total hip replacement patients." Journal of Biomechanics **40**(15): 3432-3437.
- Freccero, D. M., B. Providence, et al. (2009). "Postoperative Assessment of Vascularity of the Femoral Head After Surgical Hip Dislocation." The Journal of Arthroplasty **24**(5): 689-692.
- Ganz, R., T. J. Gill, et al. (2001). "Surgical dislocation of the adult hip." The Journal of Bone & Joint Surgery **83-B**(8): 1119-1124.
- Ganz, R., J. Parvizi, et al. (2003). "Femoroacetabular Impingement. A Cause for Osteoarthritis of the Hip." Clinical Orthopaedics and Related Research **417**: 112-120.
- Gosvig, K. K., S. Jacobsen, et al. (2008). "The Prevalence of Cam-Type Deformity of the Hip Joint: A Survey of 4151 Subjects of the Copenhagen Osteoarthritis Study." Acta Radiologica **49**(4): 436-441.
- Grotle, M., A. M. Garratt, et al. (2010). "What's in Team Rehabilitation Care After Arthroplasty for Osteoarthritis? Results From a Multicenter, Longitudinal Study Assessing Structure, Process, and Outcome." Physical Therapy **90**(1): 121-131.
- Guanche, C. A. and A. A. Bare (2006). "Arthroscopic Treatment of Femoroacetabular Impingement." Arthroscopy: The Journal of Arthroscopic and Related Surgery **22**(1): 95-106.

- Harris, W. H. (1969). "Traumatic arthritis of the hip after dislocation and acetabular fractures: treatment by mold arthroplasty. An end-result study using a new method of result evaluation." The Journal of Bone and Joint Surgery **51-A**(4): 737-755.
- Harris, W. H. (1986). "Etiology of Osteoarthritis of the Hip." Clinical Orthopaedics and Related Research **213**: 20-33.
- Hemmerich, A., H. Brown, et al. (2006). "Hip, Knee, and Ankle Kinematics of High Range of Motion Activities of Daily Living." Journal of Orthopaedic Research **24**: 770-781.
- Herck, P. V., K. Vanhaecht, et al. (2010). "Key interventions and outcomes in joint arthroplasty clinical pathways: a systematic review." Journal of Evaluation in Clinical Practice **16**: 39-49.
- Hwang, S., Y. Kim, et al. (2009). "Lower extremity joint kinetics and lumbar curvature during squat and stoop lifting." BMC Musculoskeletal Disorders **10**(15).
- Ilizaliturri Jr, V. M., L. Orozco-Rodriguez, et al. (2008). "Arthroscopic Treatment of Cam-Type Femoroacetabular Impingement." The Journal of Arthroplasty **23**(2): 226-234.
- Isear, J., J. Erickson, et al. (1997). "EMG analysis of lower extremity muscle recruitment patterns during an unloaded squat." Medicine & Science in Sports & Exercise **29**(4): 532-539.
- Ito, K., M. Leunig, et al. (2004). "Histopathologic Features of the Acetabular Labrum in Femoroacetabular Impingement." Clinical Orthopaedics and Related Research **429**: 262-271.
- Ito, K., M.-A. Minka-II, et al. (2001). "Femoroacetabular impingement and the cam-effect. A MRI-based quantitative anatomical study of the femoral head-neck offset." The Journal of Bone & Joint Surgery **83-B**(2): 171-176.
- Janssen, W., H. Bussmann, et al. (2002). "Determinants of the Sit-to-Stand Movement: A Review." Physical Therapy **82**(9): 866-875.
- Judge, J. O., R. B. Davis III, et al. (1996). "Step Length Reductions in Advanced Age: The Role of Ankle and Hip Kinetics." The Journals of Gerontology **51A**(6): M303-M312.
- Kadaba, M. P., H. K. Ramakrishnan, et al. (1990). "Measurement of Lower Extremity Kinematics During Level Walking." Journal of Orthopaedic Research **8**: 383-392.
- Kadaba, M. P., H. K. Ramakrishnan, et al. (1989). "Repeatability of Kinematic, Kinetic, and Electromyographic Data in Normal Adult Gait." Journal of Orthopaedic Research **7**: 849-860.
- Kennedy, M. J., M. Lamontagne, et al. (2009a). "The effect of cam femoroacetabular impingement on hip maximal dynamic range of motion." Journal of Orthopedics **1**(1): 41-50.
- Kennedy, M. J., M. Lamontagne, et al. (2009b). "Femoroacetabular impingement alters hip and pelvic biomechanics during gait. Walking biomechanics of FAI." Gait & Posture **30**: 41-44.
- Kerrigan, D. C., M. K. Todd, et al. (1998). "Gender differences in joint biomechanics during walking." American Journal of Physical Medicine & Rehabilitation **77**: 2-7.
- Kim, Y.-J. and M. B. Millis (2005). "Safe Surgical Dislocation of the Hip." Operative Techniques in Orthopaedics **15**: 338-344.
- Kim, Y. T. and H. Azuma (1995). "The Nerve Endings of the Acetabular Labrum." Clinical Orthopaedics and Related Research **320**: 176-181.
- Kirkwood, R. N., E. G. Culham, et al. (1999). "Hip Moments During Level Walking, Stair Climbing, and Exercise in Individuals Aged 55 Years or Older." Physical Therapy **79**(4): 360-370.

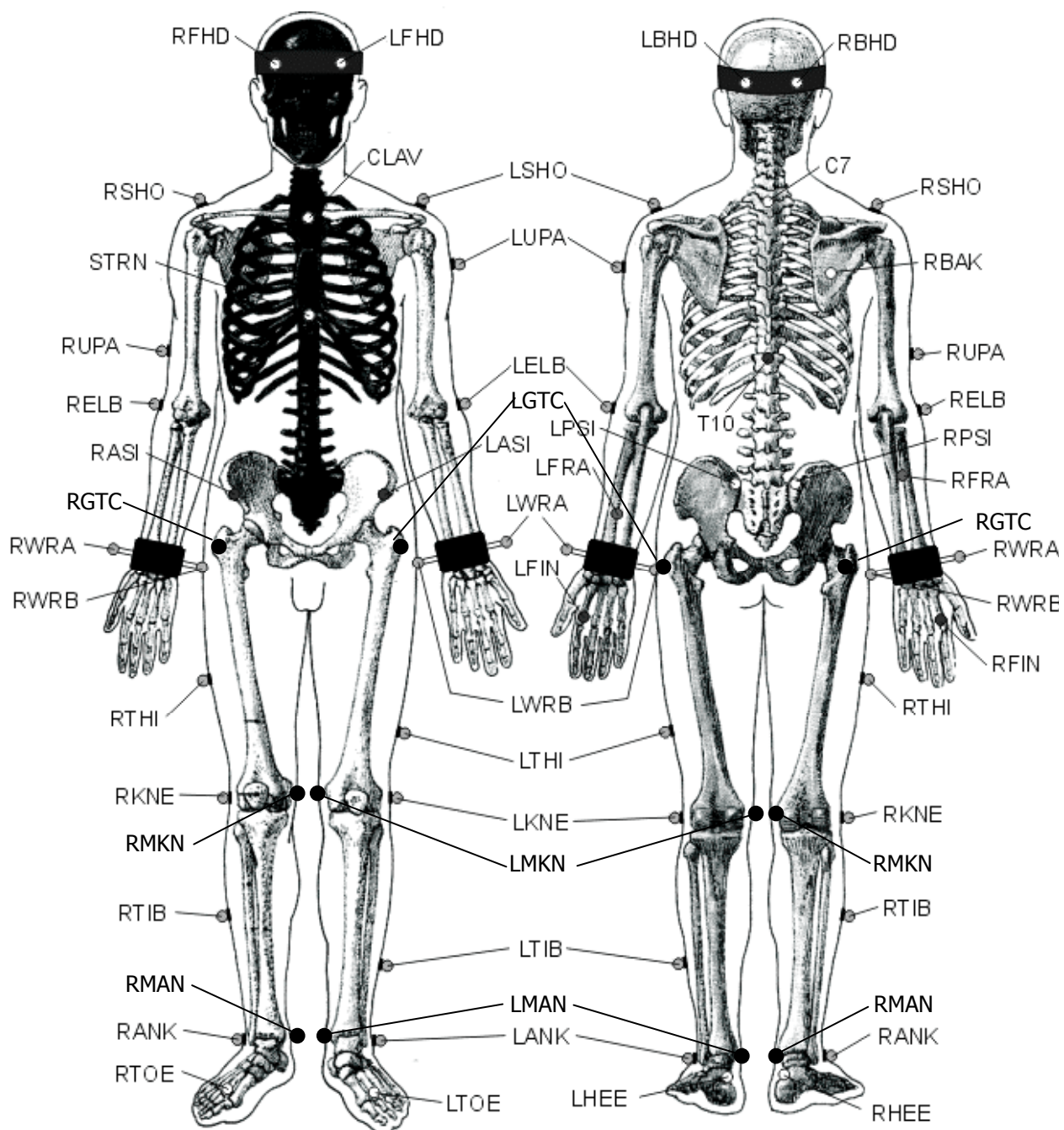
- Kloen, P., M. Leunig, et al. (2002). "Early lesions of the labrum and acetabular cartilage in osteonecrosis of the femoral head." The Journal of Bone & Joint Surgery **84-B**: 66-69.
- Konishi, N. and T. Mieno (1993). "Determination of acetabular coverage of the femoral head with use of a single anteroposterior radiograph. A new computerized technique." J Bone Joint Surg Am **75**(9): 1318-1333.
- Kubiak-Langer, M., M. Tannast, et al. (2007). "Range of Motion in Anterior Femoroacetabular Impingement." Clinical Orthopaedics and Related Research **458**: 117-124.
- Lamontagne, M., N. Brisson, et al. (2011). "Preoperative and Postoperative Lower-Extremity Joint and Pelvic Kinematics During Maximal Squatting of Patients with Cam Femoro-Acetabular Impingement." The Journal of Bone and Joint Surgery (Am) **93**: 40-45.
- Lamontagne, M., M. J. Kennedy, et al. (2009). "The Effect of Cam FAI on Hip and Pelvic Motion during Maximum Squat." Clinical Orthopaedics and Related Research **467**: 645-650.
- Laude, F., T. Boyer, et al. (2007). "Anterior femoroacetabular impingement." Joint Bone Spine **74**: 127-132.
- Lavigne, M., J. Parvizi, et al. (2004). "Anterior Femoroacetabular Impingement. Part I. Techniques of Joint Preserving Surgery." Clinical Orthopaedics **418**: 61-66.
- Leardini, A., L. Chiari, et al. (2005). "Human movement analysis using stereophotogrammetry. Part 3: Soft tissue artifact assessment and compensation." Gait & Posture **21**: 212-225.
- Leunig, M., M. Beck, et al. (2005). "Femoroacetabular Impingement: Etiology and Surgical Concept." Operative Techniques in Orthopaedics **15**: 247-255.
- Leunig, M., W. J. Robertson, et al. (2007). "Femoroacetabular Impingement: Diagnosis and Management, Including Open Surgical Technique." Operative Techniques in Sports Medicine **15**(4): 178-188.
- Levine, B., B. Kaplanek, et al. (2009). "Pilates Training for Use in Rehabilitation after Total Hip and Knee Arthroplasty." Clinical Orthopaedics and Related Research **467**: 1468-1475.
- Liebs, T. R., W. Herzberg, et al. (2010). "Ergometer Cycling After Hip or Knee Replacement Surgery: A Randomized Controlled Trial." The Journal of Bone and Joint Surgery (Am) **92**: 814-822.
- Lincoln, M., K. Johnston, et al. (2009). "Combined Arthroscopic and Modified Open Approach for Cam Femoroacetabular Impingement: A Preliminary Experience." Arthroscopy: The Journal of Arthroscopic and Related Surgery **25**(4): 392-399.
- Lindemann, U., C. Becker, et al. (2006). "Gait analysis and WOMAC are complimentary in assessing functional outcome in total hip replacement." Clinical Rehabilitation **20**: 413-420.
- Manabe, Y., K. Shimada, et al. (2007). "Effect of slow movement and stretch-shortening cycle on lower extremity muscle activity and joint moments during squat." Journal of Sports Medicine and Physical Fitness **47**: 1-12.
- Mann, R. A. and J. Hagy (1980). "Biomechanics of walking, running, and sprinting." American Journal of Sports Medicine **8**: 345-350.

- Mardones, R. M., C. Gonzalez, et al. (2006). "Surgical Treatment of Femoroacetabular Impingement: Evaluation of the Effect of the Size of the Resection." The Journal of Bone & Joint Surgery **88-A**: 84-91.
- Marker, D. R., T. M. Seyler, et al. (2010). "Does commitment to rehabilitation influence clinical outcome of total hip resurfacing arthroplasty?" Journal of Orthopaedic Surgery and Research **5**: 20-27.
- Meyer, D. C., M. Beck, et al. (2006). "Comparison of Six Radiographic Projections to Assess Femoral Head/Neck Asphericity." Clinical Orthopaedics and Related Research **445**: 181-185.
- Miki, H., N. Sugano, et al. (2004). "Recovery of walking speed and symmetrical movement of the pelvis and lower extremity joints after unilateral THA." Journal of Biomechanics **37**: 443-455.
- Mills, P. M. and R. S. Barrett (2001). "Swing phase mechanics of healthy young and elderly men." Human Movement Science **20**: 427-446.
- Möckel, G., C. Perka, et al. (2003). "The influence of walking speed on kinetic and kinematic parameters in patients with osteoarthritis of the hip using a force-instrumented treadmill and standardised gait speeds." Archives of Orthopaedic and Trauma Surgery **123**: 278-282.
- Mulholland, S. J. and U. P. Wyss (2001). "Activities of daily living in non-Western cultures: range of motion requirements for hip and knee joint implants." International Journal of Rehabilitation Research **24**: 191-198.
- Murray, R. O. (1965). "The aetiology of primary osteoarthritis of the hip." The British Journal of Radiology **38**: 810-824.
- Myers, S. R., H. Eijer, et al. (1999). "Anterior Femoroacetabular Impingement After Periacetabular Osteotomy." Clinical Orthopaedics and Related Research **363**: 93-99.
- Nötzli, H. P., T. F. Wyss, et al. (2002). "The contour of the femoral head-neck junction as a predictor for the risk of anterior impingement." The Journal of Bone & Joint Surgery **84-B**: 556-560.
- Pai, Y. C. and M. W. Rogers (1991). "Speed variation and resultant joint torques during sit-to-stand." Archives of Physical Medicine and Rehabilitation **72**(11): 881-885.
- Peters, C. L. and J. A. Erickson (2006). "Treatment of Femoro-Acetabular Impingement with Surgical Dislocation and Débridement in Young Adults." The Journal of Bone & Joint Surgery **88-A**(8): 1735-1741.
- Philippon, M. J., R. B. Maxwell, et al. (2007). "Clinical presentation of femoroacetabular impingement." Knee Surgery, Sports Traumatology, Arthroscopy **15**: 1041-1047.
- Philippon, M. J. and M. L. Schenker (2006). "Arthroscopy for the Treatment of Femoroacetabular Impingement in the Athlete." Clinical Sports Medicine **25**: 299-308.
- Philippon, M. J. and M. L. Schenker (2006). "A New Method for Acetabular Rim Trimming and Labral Repair." Clinical Sports Medicine **25**: 293-297.
- Rab, G. T. (1999). "The Geometry of Slipped Capital Femoral Epiphysis: Implications for Movement, Impingement, and Corrective Osteotomy." Journal of Pediatric Orthopaedics **19**(4): 419-424.
- Rahmann, A. E., S. G. Brauer, et al. (2009). "A Specific Inpatient Aquatic Physiotherapy Program Improves Strength After Total Hip or Knee Replacement Surgery: A Randomized Controlled Trial." Archives of Physical Medicine and Rehabilitation **90**: 745-755.

- Reinschmidt, C., A. J. van den Bogert, et al. (1997). "Effect of skin movement on the analysis of skeletal knee joint motion during running." Journal of Biomechanics **30**(7): 729-732.
- Reynolds, D., J. Lucas, et al. (1999). "Retroversion of the acetabulum. A cause of hip pain." J Bone Joint Surg Br **81**(2): 281-288.
- Sampson, T. G. (2005). "Arthroscopic Treatment of Femoroacetabular Impingement." Techniques in Orthopaedics **20**(1): 56-62.
- Schultz, A. B., N. B. Alexander, et al. (1992). "Biomechanical analyses of rising from a chair." Journal of Biomechanics **25**(12): 1383-1391.
- Singh, U. and S. S. Wason (1988). "Multiaxial orthotic hip joint for squatting and cross-legged sitting with hip-knee-ankle-foot-orthosis." Prosthetics and Orthotics International **12**: 101-102.
- Stähelin, L., T. Stähelin, et al. (2008). "Arthroscopic Offset Restoration in Femoroacetabular Cam Impingement: Accuracy and Early Clinical Outcome." Arthroscopy: The Journal of Arthroscopic and Related Surgery **24**(1): 51-57.
- Strickland, E. M., M. Fares, et al. (1992). "In Vivo Acetabular Contact Pressures During Rehabilitation, Part I: Acute Phase." Physical Therapy **72**(10): 691-698.
- Stulberg, S. D., L. D. Cordell, et al. (1975). Unrecognized childhood hip disease: a major cause of idiopathic osteoarthritis of the hip. Proceedings of the third open scientific meeting of the hip society, St. Louis.
- Tannast, M., D. Goricki, et al. (2008). "Hip Damage Occurs at the Zone of Femoroacetabular Impingement." Clinical Orthopaedics and Related Research **466**: 273-280.
- Tanzer, M. and N. Noiseux (2004). "Osseous Abnormalities and Early Osteoarthritis." Clinical Orthopaedics and Related Research **429**: 170-177.
- Thorborg, K., E. M. Roos, et al. (2009). "Validity, Reliability And Responsiveness Of Patient-Reported Outcome Questionnaires When Assessing Hip And Groin Disability: A Systematic Review." British Journal of Sports Medicine: Online.
- Vogt, L., W. Banzer, et al. (2004). "Muscle Activation Pattern of Hip Arthroplasty Patients in Walking." Research in Sports Medicine **12**: 191-199.
- Ware Jr, J. E. and C. D. Sherbourne (1992). "The MOS 36-item short-form health survey (SF-36). I. Conceptual framework and item selection." Medical Care **30**(6): 473-483.
- Weiland, D. E. and M. J. Philippon (2005). "Arthroscopic Technique of Femoroacetabular Impingement." Operative Techniques in Orthopaedics **15**: 256-260.
- Winter, D. A. (1983). "Biomechanical motor patterns in normal walking." Journal of Motor Behavior **15**(4): 302-330.
- Winter, D. A. (2005). Biomechanics and Motor Control of Human Movement. New Jersey, USA, John Wiley & Sons Inc.
- Wisniewski, S. J. and B. Grogg (2006). "Femoroacetabular Impingement. An overlooked Cause of Hip Pain." American Journal of Physical Medicine & Rehabilitation **85**(6): 546-549.
- Woltring, H. J. (1986). "A Fortran package for generalized, cross-validatory spline smoothing and differentiation." Advances in Engineering Software **8**(2): 104-113.

APPENDIX A

University of Ottawa Motion Analysis Model



APPENDIX B

University of Ottawa Motion Analysis Model Marker Placement

Head	
LFHD & RFHD	Left & right temple
LBHD & RBHD	Left & right back of head
Torso	
C7	7th cervical vertebrae
T10	10th thoracic vertebrae
CLAV	Jugular notch
STRN	Xiphoid process
RBAK	Middle of right scapula
Arms	
LSHO & RSHO	Left & right acromio-clavicular joint
LUPA & RUPA	Left & right upper arm
LELB & RELB	Left & right lateral epicondyle
LFRA & RFRA	Left & right forearm
LWRA & RWRA	Left & right wrist bar thumb side
LWRB & RWRB	Left & right wrist bar pinkie side
LFIN & RFIN	Left & right dorsum of the hand head of 2nd metacarpal
Pelvis	
LASI & RASI	Left & right anterior superior iliac spine
LPSI & RPSI	Left & right posterior superior iliac spine
LGTC & RGTC	Left & right greater trochanter
Legs	
LTHI & RTHI	Left & right lateral thigh
LMKN & RMKN	Left & right medial epicondyle of the knee
LKNE & RKNE	Left & right lateral epicondyle of the knee
LTIB & RTIB	Left & right lateral shank
LANK & RANK	Left & right lateral malleolus
LMAN & RMAN	Left & right medial malleolus
Feet	
LTOE & RTOE	Left & right 2nd metatarsal head of foot
LHEE & RHEE	Left & right posterior calcaneus

APPENDIX C

Height-Adjustable Bench



APPENDIX D (i)

Health Sciences and Science Research Ethics Board Approval

File Number: H01-07-04

Date (mm/dd/yyyy): 04/08/2010



Université d'Ottawa **University of Ottawa**
 Service de subventions de recherche et déontologie Research Grants and Ethics Services

Ethics Approval Notice Health Sciences and Science REB

Principal Investigator / Supervisor / Co-investigator(s) / Student(s)

<u>First Name</u>	<u>Last Name</u>	<u>Affiliation</u>	<u>Role</u>
Mario	Lamontagne	Health Sciences / Human Kinetics	Principal Investigator
Paul	Beaulé	Medicine / Medicine	Co-Principal Investigator
Kawan	Rakhra		Co-Principal Investigator
Matthew	Kennedy	Health Sciences / Human Kinetics	Research Assistant

File Number: H01-07-04

Type of Project: Professor

Title: The Effect of Femoroacetabular Impingement on Hip Biomechanics during Level Walking, Sit-to-Stand, Stand-to-Sit and Maximal Squatting Depth

Renewal Date (mm/dd/yyyy)	Expiry Date (mm/dd/yyyy)	Approval Type
03/28/2010	03/27/2011	Ia

(Ia: Approval, Ib: Approval for initial stage only)

Special Conditions / Comments:

N/A

APPENDIX D (ii)

Health Sciences and Science Research Ethics Board Approval

File Number: H01-07-04

Date (mm/dd/yyyy): 04/08/2010



Université d'Ottawa **University of Ottawa**
 Service de subventions de recherche et déontologie Research Grants and Ethics Services

Ethics Approval Notice Health Sciences and Science REB

Principal Investigator / Supervisor / Co-investigator(s) / Student(s)

<u>First Name</u>	<u>Last Name</u>	<u>Affiliation</u>	<u>Role</u>
Mario	Lamontagne	Health Sciences / Human Kinetics	Principal Investigator
Paul	Beaulé	Medicine / Medicine	Co-Principal Investigator
Kawan	Rakhra		Co-Principal Investigator
Matthew	Kennedy	Health Sciences / Human Kinetics	Research Assistant

File Number: H01-07-04

Type of Project: Professor

Title: The Effect of Femoroacetabular Impingement on Hip Biomechanics during Level Walking, Sit-to-Stand, Stand-to-Sit and Maximal Squatting Depth

Renewal Date (mm/dd/yyyy)	Expiry Date (mm/dd/yyyy)	Approval Type
03/28/2010	03/27/2011	Ia

(Ia: Approval, Ib: Approval for initial stage only)

Special Conditions / Comments:

N/A

APPENDIX D (iii)

Health Sciences and Science Research Ethics Board Approval

Confidentiality Pledge

Ethics File # H 01-07-04

Study Title: The Effect of Femoroacetabular Impingement on Hip Biomechanics during Level Walking, Sit-to-Stand, Stand-to-Sit and Maximal Squatting Depth. Part II of Reconstruction and Modeling for Surgical Pre-operative Planning.

I NICHOLAS BRISSON commit to total confidentiality when dealing with any data, information or documents concerning the participants involved in this study. I will not divulge or discuss any participants' names personal information or other sensitive information from this study with anyone other than the authorized persons listed in the Ethics File # H 01-07-04 as part of the research team.

NICHOLAS BRISSON

 Researcher's Name (Printed)

 Researcher's Signature

OCTOBER 21/09

 Date

MATTHEW KENNEDY

 Witness's Name (Printed)

 Witness's Signature

OCT. 21, 2009.

 Date